

## Cervical Arterial Dissections and Association With Cervical Manipulative Therapy

### A Statement for Healthcare Professionals From the American Heart Association/American Stroke Association

*Endorsed by the American Association of Neurological Surgeons and Congress of Neurological Surgeons*

José Biller, MD, FAHA, Chair; Ralph L. Sacco, MS, MD, FAHA, Co-Chair;  
Felipe C. Albuquerque, MD; Bart M. Demaerschalk, MD, MSc; Pierre Fayad, MD, FAHA;  
Preston H. Long, DC, PhD; Lori D. Noorollah, MD; Peter D. Panagos, MD, FAHA;  
Wouter I. Schievink, MD; Neil E. Schwartz, MD, PhD; Ashfaq Shuaib, MD, FAHA;  
David E. Thaler, MD, PhD, FAHA; David L. Tirschwell, MD, MSc;  
on behalf of the American Heart Association Stroke Council

**Purpose**—Cervical artery dissections (CDs) are among the most common causes of stroke in young and middle-aged adults. The aim of this scientific statement is to review the current state of evidence on the diagnosis and management of CDs and their statistical association with cervical manipulative therapy (CMT). In some forms of CMT, a high or low amplitude thrust is applied to the cervical spine by a healthcare professional.

**Methods**—Members of the writing group were appointed by the American Heart Association Stroke Council's Scientific Statements Oversight Committee and the American Heart Association's Manuscript Oversight Committee. Members were assigned topics relevant to their areas of expertise and reviewed appropriate literature, references to published clinical and epidemiology studies, morbidity and mortality reports, clinical and public health guidelines, authoritative statements, personal files, and expert opinion to summarize existing evidence and to indicate gaps in current knowledge.

**Results**—Patients with CD may present with unilateral headaches, posterior cervical pain, or cerebral or retinal ischemia (transient ischemic or strokes) attributable mainly to artery–artery embolism, CD cranial nerve palsies, oculosympathetic palsy, or pulsatile tinnitus. Diagnosis of CD depends on a thorough history, physical examination, and targeted ancillary investigations. Although the role of trivial trauma is debatable, mechanical forces can lead to intimal injuries of the vertebral arteries and internal carotid arteries and result in CD. Disability levels vary among CD patients with many having good outcomes, but serious neurological sequelae can occur. No evidence-based guidelines are currently available to endorse best management strategies for CDs. Antiplatelet and anticoagulant treatments are both used for prevention of local thrombus and secondary embolism. Case-control and other articles have suggested an epidemiologic association between CD, particularly vertebral artery dissection, and CMT. It is unclear whether this is due to lack of recognition of preexisting CD in these patients or due to trauma caused by CMT. Ultrasonography, computed tomographic angiography, and magnetic resonance imaging with magnetic resonance angiography are useful in the diagnosis of CD. Follow-up neuroimaging is preferentially done with noninvasive modalities, but we suggest that no single test should be seen as the gold standard.

The American Heart Association makes every effort to avoid any actual or potential conflicts of interest that may arise as a result of an outside relationship or a personal, professional, or business interest of a member of the writing panel. Specifically, all members of the writing group are required to complete and submit a Disclosure Questionnaire showing all such relationships that might be perceived as real or potential conflicts of interest.

This statement was approved by the American Heart Association Science Advisory and Coordinating Committee on November 29, 2013. A copy of the document is available at <http://my.americanheart.org/statements> by selecting either the “By Topic” link or the “By Publication Date” link. To purchase additional reprints, call 843-216-2533 or e-mail [kelle.ramsay@wolterskluwer.com](mailto:kelle.ramsay@wolterskluwer.com).

The American Heart Association requests that this document be cited as follows: Biller J, Sacco RL, Albuquerque FC, Demaerschalk BM, Fayad P, Long PH, Noorollah LD, Panagos PD, Schievink WI, Schwartz NE, Shuaib A, Thaler DE, Tirschwell DL; on behalf of the American Heart Association Stroke Council. Cervical arterial dissections and association with cervical manipulative therapy: a statement for healthcare professionals from the American Heart Association/American Stroke Association. *Stroke*. 2014;45:3155–3174.

Expert peer review of AHA Scientific Statements is conducted by the AHA Office of Science Operations. For more on AHA statements and guidelines development, visit <http://my.americanheart.org/statements> and select the “Policies and Development” link.

Permissions: Multiple copies, modification, alteration, enhancement, and/or distribution of this document are not permitted without the express permission of the American Heart Association. Instructions for obtaining permission are located at [http://www.heart.org/HEARTORG/General/Copyright-Permission-Guidelines\\_UCM\\_300404\\_Article.jsp](http://www.heart.org/HEARTORG/General/Copyright-Permission-Guidelines_UCM_300404_Article.jsp). A link to the “Copyright Permissions Request Form” appears on the right side of the page.

© 2014 American Heart Association, Inc.

*Stroke* is available at <http://stroke.ahajournals.org>

DOI: 10.1161/STR.0000000000000016

**Conclusions**—CD is an important cause of ischemic stroke in young and middle-aged patients. CD is most prevalent in the upper cervical spine and can involve the internal carotid artery or vertebral artery. Although current biomechanical evidence is insufficient to establish the claim that CMT causes CD, clinical reports suggest that mechanical forces play a role in a considerable number of CDs and most population controlled studies have found an association between CMT and VAD stroke in young patients. Although the incidence of CMT-associated CD in patients who have previously received CMT is not well established, and probably low, practitioners should strongly consider the possibility of CD as a presenting symptom, and patients should be informed of the statistical association between CD and CMT prior to undergoing manipulation of the cervical spine. (*Stroke*. 2014;45:3155-3174.)

**Key Words:** AHA Scientific Statements ■ cervical artery dissection ■ vertebral artery dissection ■ carotid artery dissection ■ cervical manipulative therapy ■ cervical adjustment ■ diagnosis of cervical artery dissection

Cervical artery dissection (CD) is an important cause of stroke in young and middle-aged patients. Although accounting for only 2% of all ischemic strokes, CD accounts for 8% to 25% of stroke in patients <45 years of age.<sup>1,2</sup> Internal carotid artery (ICA) dissection has an annual incidence of 2.5 to 3 per 100 000 patients,<sup>3</sup> whereas vertebral artery (VA) dissection (VAD) has an annual incidence of 1 to 1.5 per 100 000 people.<sup>4,5</sup> These rates are likely to be an underestimation because cases of asymptomatic CD can go undiagnosed. In a North American and 2 European cohorts, the mean age for CD was 45.8,<sup>8</sup> 44.0, and 45.3 years, respectively.<sup>6,9</sup> In the North American population, 50% to 52% of the CD patients were women.<sup>8,10,11</sup> A slight male predominance (55.4%) was reported in a European multicenter hospital-based series.<sup>6,9</sup> The Cervical Artery Dissection and Ischemic Stroke Patients (CADISP) Study, an international observational study focusing on risk factors and short-term outcomes of CD and ischemic stroke in young adults, evaluated a case-control population of 983 consecutive CD patients and 658 ischemic stroke controls and found that CD was more common in men (56.7% versus 43.3%;  $P<0.001$ ) and in men who tended to be older than the women (46.4 versus 41.0 years;  $P<0.001$ ).<sup>12</sup>

The underlying pathogenesis responsible for spontaneous CDs is unknown. Factors associated with CD are shown in Table 1. Ultrastructural aberrations of dermal collagen fibrils and elastic fibers have been reported in ≈50% of patients with spontaneous CDs in whom there was no prior diagnosis of a connective tissue disorder,<sup>33</sup> suggesting a molecular defect in the biosynthesis of the extracellular matrix.<sup>58</sup> Seasonal variability, particularly increased CD occurring more often in autumn or winter than in the spring or summer, has also been demonstrated and believed to be a result of increased occurrence of infection or weather-related changes in blood pressure.<sup>43,59,60</sup> One study found a significant association between an elevated C-reactive protein and dissection that was not present in patients with cryptogenic or large-artery strokes (adjusted odds ratio [OR] 7.9;  $P<0.004$ ).<sup>39</sup> Results from the CADISP Study have suggested that hypercholesterolemia, obesity, and increased body mass index are less commonly associated with CD than ischemic stroke.<sup>61</sup>

Dissections can be either spontaneous or traumatic.<sup>17,62</sup> Trauma can range from the severe, such as that which might occur in a high-speed motor vehicle crash, to the more subtle (ie, coughing, sneezing, or countless sporting activities such as heavy lifting, golf, tennis, and yoga).<sup>14,63</sup> The frequent temporal association of dissections with everyday “traumatic”

activities has led to confusion about how to define spontaneous versus traumatic dissections and to what extent mechanical forces precipitate dissections in the absence of an underlying predisposition. Despite various confounding factors, including recall bias and nonuniform definitions of traumatic activities, it is well established that mechanical forces play a role in a considerable number of CDs. Traumatic CDs can occur as the result of major blunt or penetrating trauma.<sup>13</sup> In patients with blunt cervical trauma, the prevalence of CD is ≈1% to 2%, and this risk increases as the intensity of the external force increases such as that seen with concomitant major thoracic injuries, severe facial fractures, skull base fractures, and traumatic brain injury.

**Table 1. Factors Associated With CD**

Major and minor cervical trauma <sup>13-17</sup>
Arterial hypertension <sup>18-20</sup>
Young age <sup>12</sup>
Current use of oral contraceptives <sup>21</sup>
Migraine <sup>22-24</sup>
Fibromuscular dysplasia <sup>11,25-32</sup>
Ultrastructural connective tissue abnormalities <sup>33</sup>
Vascular subtype of Ehlers-Danlos syndrome <sup>34</sup>
Marfan syndrome <sup>18,35</sup>
Turner syndrome <sup>19,36</sup>
Williams syndrome <sup>37</sup>
Familial cases <sup>18,38</sup>
Hereditary hemochromatosis <sup>39</sup>
Osteogenesis imperfecta type I <sup>40</sup>
$\alpha$ 1-Antitrypsin deficiency <sup>41,42</sup>
677T genotype MTHFR <sup>43-45</sup>
Hyperhomocysteinemia <sup>46</sup>
Cystic medial necrosis of intracranial vessels <sup>47</sup>
Styloid process length <sup>48</sup>
ICAM-1 E4690 K gene polymorphism <sup>49</sup>
Autosomal-dominant polycystic kidney disease <sup>50</sup>
Infections <sup>51-54</sup>
Moyamoya disease <sup>55</sup>
Lentiginosis <sup>56</sup>
Vessel redundancies (coils, kinks, loops), especially if bilateral <sup>57</sup>

CD indicates cervical artery dissection; ICAM-1, intracellular adhesion molecule-1; and MTHFR, methylenetetrahydrofolate reductase.

CDs also can occur with minor trauma characterized by hyperextension, rotation, or lateroversion of the neck; various sporting activities; whiplash injuries; stretching and sudden neck movements; and violent vomiting or coughing.<sup>14,63</sup> Among patients with CD, the reported prevalence of trivial trauma is estimated to be between 12% and 34%.<sup>21,64,65</sup> The relationship, if any, of CD to any of these minor cervical traumas is often difficult to discern in an individual. Cervical manipulative therapy (CMT) has been demonstrated to be associated with CD in several studies.<sup>66–68</sup>

## Methods

Writing group members were nominated by the committee chair and co-chair on the basis of their previous work in relevant topic areas and were approved by the American Heart Association (AHA) Stroke Council's Scientific Statement Oversight Committee and the AHA's Manuscript Oversight Committee. At the AHA's invitation, the American Chiropractic Association designated a representative to participate in the development of this paper but who elected not to be named. All members of the writing group had the opportunity to comment on and approved the final version of this document. The document underwent extensive AHA internal peer review, Stroke Council Leadership review, and Scientific Statements Oversight Committee review before consideration and approval by the AHA Science Advisory and Coordinating Committee.

## Cervical Manipulative Therapy

CMT is a broad term that encompasses cervical spine manipulation by any healthcare professional and includes cervical adjustments by chiropractors. Other terms that have been used in the literature include chiropractic manipulative therapy, chiropractic adjustment or manipulation, manual physiotherapy, manual therapy, spinal adjustive manipulation, spinal manipulation, and spinal manipulative therapy. Spinal manipulation is a therapeutic intervention in which a high- or low-velocity, low-amplitude thrust is applied to the spine.<sup>69</sup> Other forms of CMT that do not use a thrust are also in use. The majority of spinal manipulations performed in North America are done by chiropractors<sup>70,71</sup>; however, they are also done by members of the allopathic, osteopathic, and physical therapy/physiotherapy professions.<sup>72–76</sup>

According to the 2007 US statistics on alternative medicine, at least 38% of US adults and 12% of children use some form of alternative medicine, including chiropractic and osteopathic manipulations, mainly for back, neck, and joint pain.<sup>77</sup> The chiropractic profession is common in the United States, Canada, and Australia but less so elsewhere. Chiropractic is the largest alternative medical profession in the United States and the third largest clinical profession granting doctorates behind medicine and dentistry. Annually, an estimated 10% of the North American population visits chiropractors; the majority of the visits are for low back pain.<sup>78,79</sup>

Data on the effectiveness of CMT for neck pain are sparse and questionable.<sup>73,80–85</sup> The most recent Cochrane review consisting of some low-quality trials found that the effect of cervical manipulation was comparable to that of mobilization, which does not include a thrust.<sup>80–82</sup> Two studies, published

since this systematic review, investigated the effects of cervical manipulation on neck pain. Bronfort et al<sup>183a</sup> found that cervical manipulation, together with other physical interventions, was as effective as a home exercise program and that each was more effective than treatment with  $\geq 1$  of the following: nonsteroidal anti-inflammatory drugs, acetaminophen, muscle relaxants, and narcotics. Dunning et al<sup>73</sup> compared cervical and thoracic thrust manipulation with cervical and thoracic nonthrust mobilization for patients with neck pain and found an improvement in the manipulation (versus mobilization) group at 48 hours.

## Association of CD and CMT

There has been considerable discussion and debate about the association between CMT and CD.<sup>68,83–85</sup> The majority of the literature associating CMT with VAD/vertebrobasilar artery territory stroke is from case reports/case series,<sup>66,83,83a,86–105</sup> surveys,<sup>106,107</sup> or expert opinions.<sup>108–113</sup> Given the very low incidence of CD,<sup>8,104,114,115</sup> the best study design that has been used to date to determine whether CMT may cause CD is the case-control study.<sup>116</sup> There have been 6 reported case-control studies of CD that have evaluated an association with CMT.<sup>15,67,84,85,117,118</sup>

Two of these case-control studies were very small and of lower quality.<sup>15,85</sup> In a small retrospective study from Germany, 47 consecutive patients <60 years of age with CD were compared with 47 consecutive age-matched patients with stroke of another cause.<sup>15</sup> Although cervical manipulations within 30 days of stroke were twice as frequent in CD patients (21.3%, 10 of 47) compared with non-CD stroke controls (10.6%, 5 of 47), there was no significant difference in this small study. In a small retrospective study, Thomas and colleagues<sup>85</sup> reviewed records of 47 dissection patients and 43 controls <55 years of age with stroke from another cause. Mild mechanical trauma to the head and neck was significantly associated with craniocervical arterial dissection (OR, 23.53; 95% confidence interval [CI], 6.31–87.70). “Neck manual therapy” was reported in 23% of CD cases (8 vertebrobasilar artery, 3 ICA) and only 2% of the non-CD stroke cases (OR, 12.67; 95% CI, 1.58–104.28). As a result of their preliminary observations, the authors proposed a prospective study.<sup>119</sup>

Four larger case-control studies found an association between CMT and VAD/vertebrobasilar artery territory stroke in young patients (<45 years of age) with reported ORs of 3 to 12,<sup>67</sup> 5.5,<sup>84</sup> 6.6,<sup>117</sup> and 3.6 to 11.9,<sup>118</sup> respectively (Table 2). Two of the 4 studies specifically evaluated chiropractic visits.<sup>67,84</sup> Rothwell and colleagues<sup>84</sup> reviewed the Ontario administrative database from 1993 to 1998 to identify patients with vertebrobasilar artery territory stroke. Of the 582 cases identified, which were age and sex matched to 4 controls from the Ontario general population, they determined that young patients (age <45 years) with vertebrobasilar territory stroke were 5 times more likely than controls to have visited a chiropractor within 1 week of the event (OR, 5.02; 95% CI, 1.32–43.87). Among the 112 stroke cases <45 years of age, 4.5% visited a chiropractor within 1 week of the stroke compared with 0.9% of the controls.

Smith and associates<sup>117</sup> used a case-control study design to review patients <60 years of age with CD (n=151: 51 with CD and ischemic stroke or transient ischemic attack and 100 controls with strokes of non-CD causes) from 1995 to 2000 at 2 academic medical centers to determine whether CMT was

**Table 2. Case-Control Studies on the Association of Stroke and CMT**

Author	Methodology	Population	Measured Events
Rothwell et al, <sup>84</sup> 2001	Population-based nested case-control design	All Ontario people admitted to acute care facility with a diagnosis of posterior circulation stroke from January 1993–December 1998	Age <45 y Posterior circulation stroke within 1 wk of DC visit: OR 5.03 (95% CI, 1.32–43.87) Number of cervical chiropractic visits previous month (≥3 visits) OR, 4.98 (95% CI, 1.34–18.57) Age >45 y Posterior circulations stroke within 1 wk of DC visit: OR, 0.64 (95% CI, 0.25–1.67) Number of cervical chiropractic visits previous month (≥3 visits) OR, 1.60 (95% CI, 0.31–8.25)
Smith et al, <sup>117</sup> 2003	Institutional database query nested-case control study design	Combined databases of 2 California academic stroke centers for all patients with acute ischemic stroke or TIA from 1995–2000. 1107 cohort, 151 dissections, 306 other identified strokes randomly selected as controls, age and sex matched. Final study group: 51 CAD and 100 controls selected	Pain before stroke/TIA All dissections (n=51): OR, 4.6 (95% CI, 2.1–10) VAD (n=25): OR 3.8 (95% CI, 1.3–11) ICAD (n=26): OR 4.7 (95% CI, 1.7–13) SMT within 30 d All dissections (n=51): NS VAD (n=25): 6.6 (95% CI, 1.4–30) ICAD (n=26): NS
Cassidy et al, <sup>67</sup> 2008	Population-based case-control and case-crossover study	Cases: All residents of Ontario (109 020 875 person-years over 9 y) with posterior circulation strokes admitted to Ontario, Canada, hospitals, identified from discharge and OHIP databases. 818 posterior circulation strokes per 100 million person-years. 3164 controls matched to cases. Case-controls: 4 age- and sex-matched controls randomly selected from the Registered Persons Database (listing of all healthcare numbers for Ontario)	Age <45 y Posterior circulation stroke within 1 wk of any visit DC: OR, 2.41 (95% CI, 0.98–5.95) PCP: OR, 2.90 (95% CI, 1.64–5.13) Posterior circulation stroke within 1 wk of headache of cervical DC visit DC: OR, 3.11 (95% CI, 1.16–8.35) PCP: OR, 20.00 (95% CI, 4.38–91.28) Age >45 y Posterior circulation stroke within 1 wk of any visit DC: OR, 0.30 (95% CI, 0.12–0.77) PCP: OR, 2.30 (95% CI, 2.85–3.85) Posterior circulation stroke within 1 wk of headache of cervical DC visit DC: OR 1.18 (95% CI, 0.16–1.66) PCP: OR 6.99 (95% CI, 3.93–12.44)
Engelter et al, <sup>118</sup> 2013	Multicenter case-control study (Cervical Artery Dissection and Ischemic Stroke Patients) study in 18 centers in 8 countries designed to assess determinants of CD	Cases: 966 cases of CD Controls: 651 age- and sex-matched non-CD-IS; 280 healthy subjects.	Any trauma: OR, 7.6 (95% CI, 5.6–10.2) vs non-CD-IS, OR, 3.7 (95% CI, 2.4–5.56) vs healthy subjects CMT: OR, 11.9 (95% CI, 4.28–33.2) vs non-CD-IS, OR, 3.6 (95% CI, 1.23–10.7) vs healthy subjects

CD indicates cervical artery dissection; CI, confidence interval; CMT, cervical manipulative therapy; DC, doctor of chiropractic; ICAD, internal carotid artery dissection; non-CD-IS, ischemia from other causes; NS, not significant; OHIP, Ontario Health Insurance Program; OR, odds ratio; PCP, primary care physician; SMT, spinal manipulative therapy; TIA, transient ischemic attack; and VAD, vertebral artery dissection.

an independent risk factor for CD. All patients were matched to age and sex controls from the same registry. Among the 51 CD cases, 7 (14%) had CMT within 30 days compared with 3% of controls ( $P=0.032$ ). Results showed a 6-fold increase in vertebral CD and stroke/transient ischemic attack (OR, 6.62; 95% CI, 1.4–30.0) even after adjustment for neck pain before the stroke/transient ischemic attack in the multivariate analysis but showed no significant increase in carotid CD.

Cassidy et al<sup>67</sup> analyzed every case of vertebrobasilar artery territory distribution ischemic stroke in the province of Ontario, Canada, over a 9-year period in a population-based case-control and case-crossover design. There were 818 cases in 100 million person-years of analysis. They evaluated the association between VA territory stroke and chiropractic

visits, as well as seeing a primary care physician. For those <45 years of age, 8 cases (7.8%) had consulted a chiropractor within 7 days of the index date compared with 14 of controls (3.4%). They found an association between chiropractic visits and VA strokes. However, the risk was similar to the risk of VA stroke after seeing a primary care physician. This led the authors to conclude that chiropractic care does not appear to pose an excess risk of VA stroke and to suggest that headache or neck pain from VAD causes people to seek care from either chiropractic or medical physicians. The previous case-control studies<sup>15,84,117</sup> did not analyze the possible association with evaluation by primary care physicians, leading to possible protopathic bias.<sup>120</sup> The case selection in both the Rothwell et al<sup>84</sup> and Cassidy et al<sup>67</sup> studies included patients with stroke



in an anatomic distribution (posterior circulation), not with a given pathology (CD).

In a report from the CADISP Study Group, 966 cases of CD were compared with 651 age- and sex-matched patients with ischemic stroke from other causes, as well as 280 healthy subjects.<sup>118</sup> Prior cervical trauma was found among 40.5% of the CD cases, which was significantly greater compared with the other stroke case group (adjusted OR, 7.6; 95% CI, 5.6–10.20). CMT (not necessarily specified as chiropractic) was found to be significantly associated with CD compared with ischemic stroke from other causes (6.9% versus 0.6%; adjusted OR, 11.9; 95% CI, 4.28–33.2) and compared with healthy subjects (adjusted OR, 3.6; 95% CI, 1.23–10.7). The authors stated that their “findings suggest a clear association between CD and cervical manipulation therapy” and proposed the term mechanical trigger event as a more appropriate way to describe the variety of mechanical events reported in association with CD.

In summary, a few case-control studies suggest that CMT is associated with CD. These studies did not specifically distinguish whether the CMT included a thrust maneuver or not; the former is typically used with chiropractic manipulation. In the absence of prospective cohort or randomized studies, the current best available evidence suggests that CD, especially VAD, may be of a low incidence but could be a serious complication of CMT. Although these studies suggest an association, it is very difficult to determine causation because patients with VAD commonly present with neck pain, which may not be diagnosed prior to any CMT. Because patients with VAD commonly present with neck pain, it is possible that they seek therapy for this symptom from providers, including CMT practitioners, and that the VAD occurs spontaneously, implying that the association between CMT and VAD/vertebrobasilar artery stroke is not causal. It is also plausible that CMT could exacerbate the symptoms or the VAD and possibly increase the risk of stroke. Therefore, in the setting of neck pain or headache with focal neurological symptoms after any minor trauma, including CMT, immediate medical evaluation for possible stroke resulting from CD is warranted. The association between CMT and CD suggests that increased education of providers, including CMT providers, in diagnosing CD may be warranted. Correspondingly, patients with neck pain and without neurological symptoms after any trauma should be informed about the potential risks and benefits of receiving CMT, and practitioners should carefully consider CD prior to performing CMT.

### Cervical Spine Biomechanics and CMT

The cervical spine has a unique anatomy and complex biomechanics. Despite centuries of study,<sup>121,122</sup> a complete understanding of this topic has remained elusive.<sup>123</sup> Researchers have analyzed biomechanics of the cervical spine during spinal manipulation to determine whether manipulation may cause CD.<sup>124–131</sup>

The cervical spine is made up of 7 vertebral bodies and is divided into 4 anatomic sections: the atlas, the axis, the root (C2–C3 junction), and the column (C3–C7).<sup>132</sup> Movements of the cervical spine, including flexion, extension, rotation, and lateral flexion, are dependent on the orientation of the joint facets and are further restricted by muscles and ligaments surrounding the cervical vertebrae.<sup>132</sup> At the atlanto-occipital

junction, the only movement allowed is nodding (flexion/extension) because of the shape of the superior articular sockets, which receive the condyles of the occiput.<sup>132</sup> The atlanto-axial junction allows axial rotation as the arch of the atlas pivots around the odontoid process of the axis, with a normal reported range of motion of 50° to each side.<sup>133</sup> The lateral atlanto-axial joints, biconcave in shape, subsequently glide over one another, causing a small degree of lateral flexion and extension, which is coupled with the rotation.<sup>133</sup> The C2–C3 junction, known as the root, secures the cervical column to the upper cervical spine.<sup>133</sup> As a result of the unique shape of the joint articulations between C2 and C7, any degree of rotation is always coupled with some lateral flexion and vice versa.<sup>132–134</sup>

The VAs run through the transverse foramina of C1 through C6 and occasionally through C7.<sup>132</sup> Four segments are recognized: the prevertebral segment (V1), cervical segment (V2), atlantal segment (V3), and intracranial segment (V4).<sup>135</sup> The V1 segment is the portion from its origin at the subclavian artery to its entry into the costotransverse foramen of C6 or C5. The V2 segment travels between C6 and C2, entirely within the transverse foramina. The V3 segment takes a tortuous course between C2 to the suboccipital triangle between the atlas and the occiput, where it is covered by the atlanto-occipital membrane. The V3 segment, running horizontally in a groove on the superior aspect of the posterior arch of the atlas, adjacent to the atlanto-axial junction (C1–C2) where most rotation occurs,<sup>132</sup> is most susceptible to injury.<sup>130</sup> The V4 segment is the intracranial portion, after it has pierced the dura mater to enter the foramen magnum to join the opposite VA at the medullopontine level.

During high-velocity, low-amplitude manipulation, a controlled force is applied to a joint in a specified direction,<sup>136,137</sup> causing movement of that joint and adjacent joints in the spine.<sup>136,138</sup> The amount of force delivered during cervical spine manipulation with manual high-velocity, low-amplitude techniques on living human subjects is 100 to 150 N.<sup>136,139,140</sup> A higher peak force, between 200 and 273 N, has been reported on cadavers.<sup>141</sup> A study comparing peak force during cervical manipulation on living subjects and cadavers demonstrated considerably more force being used on cadavers.<sup>142</sup> It is important to take into account this difference when reviewing the biomechanical literature evaluating strain on these vessels because these studies were conducted with human cadavers. Moreover, all studies have shown considerably less force used in cervical manipulation compared with thoracic and lumbar manipulation.<sup>136,139,143</sup>

After studying external forces applied to the cervical spine during manipulation, researchers began attempts to quantify the force absorbed by and strain placed on the VAs during manipulation.<sup>137</sup> Using ultrasonographic crystals surgically placed in the VAs of human cadavers to measure strain, they measured 6% strain during manipulation (strain refers to the percent change in the length of the vessel from its length at neutral position). During passive range of motion and during enough extension and rotation of the neck enough to lead to vertebrobasilar ischemia, there was close to 12% strain,<sup>137</sup> more than the strain measured during cervical manipulation.<sup>127,137,141</sup>

Concern about transient compression of the VAs during cervical manipulation has resulted in many studies investigating

arterial blood flow during head rotation.<sup>125,126,131,144–147</sup> A case series using arteriography displayed partially obstructed blood flow through the contralateral VA at C1 to C2 during head rotation in patients with suspected vertebrobasilar artery ischemia.<sup>146,147</sup> Subsequent studies using duplex sonography have shown no significant change in blood flow in the VA during rotation,<sup>126</sup> simulated manipulation position,<sup>125</sup> and non-thrust manipulation.<sup>131</sup> One study also looked at blood flow in the ICA during simulated manipulation position and found no significant changes in blood flow in a healthy ICA.<sup>125</sup> No studies were identified that specifically measured blood flow during high-velocity, low-amplitude manipulation. It should be emphasized that these studies used blood flow as an outcome measurement, not the integrity of the intimal lining.

Understanding of the internal structures during cervical manipulation remains limited.<sup>123</sup> There is insufficient technology to view and measure the VA flow at the precise moment when the manipulation occurs. Current biomechanical evidence is insufficient to establish the claim that spinal manipulation causes CD, including data from a canine model showing no significant changes in VA lesions before and after cervical manipulation.<sup>128,148</sup>

### Postulated Mechanisms of Vessel Injury

As described above, the V3 segment of the VA is most often suspected of being injured during CMT, but any segment of the VAs can be involved.<sup>66,102,149–151</sup> An estimated 50% of total neck rotation occurs at the atlanto-axial joint, subjecting the VA at this level to higher bending forces than those encountered in the lower neck.<sup>88</sup> Rotation and extension of the neck predispose the VA to dissection by stretching the vessel against either the atlas or posterior atlanto-occipital membrane, which the VA penetrates as it courses superiorly into the skull.<sup>152</sup> Similarly, stretching of the VA narrows the vascular lumen, thereby possibly promoting the development of intra-arterial thrombus.<sup>153</sup> Typical movements for cervical manipulation can be rotation, lateral flexion, flexion, extension, or a combination of them.<sup>73–76</sup>

The presence of high cervical osteophytic disease or other anatomic variations may predispose to or increase the likelihood of VA injury during extension and rotation of the head.<sup>154</sup> Furthermore, the VA between C1 and C2 is covered by the oblique capitis and intertransverse muscles, which may further compress the artery during rotation and enhance the risk of arterial injury and subsequent thrombosis.<sup>154</sup>

Dissection of the VA can propagate rostrally to involve the intracranial (V4) segment and the basilar artery.<sup>66</sup> Isolated injuries to the V4 segment are likely the result of torsion of the vessel as it pierces the dura mater.<sup>66</sup> Dissecting aneurysms of this arterial segment can produce subarachnoid hemorrhage (SAH), although this has not been associated with CMT.<sup>66,88,148</sup>

The ICA may potentially be injured during cervical manipulation.<sup>155–157</sup> With extension and lateral flexion of the head, the artery becomes fixed in place, abutting the upper cervical vertebrae.<sup>156</sup>

### Location of Arterial Dissections and CMT

ICAs are strained during CMT at a level lower than activities of daily living.<sup>158</sup> The ICA is more freely mobile and is

thought to be less likely than the VA to be involved in dissections probably secondary to CMT.<sup>150</sup> ICA dissections (ICADs) typically begin a few centimeters rostral to the bifurcation and may extend up to or beyond the petrous canal. CDs can affect both extracranial and intracranial segments of the ICA and VA. ICADs are less likely to extend intracranially than VADs; the reason may be that the VAs pass through the relatively large foramen magnum, whereas the petrous canal of the ICA is more anatomically restrictive.<sup>1</sup> The ICA can also abut bony structures with movements of the neck; this is likely a result of stretch or compression against the processes of the upper cervical vertebrae or against the petrous bone as the ICA enters the skull base.<sup>63,156,159</sup>

In general, ICAD has been thought to occur more frequently than VAD, but there clearly is variability, depending on the population studied. Most series have combined spontaneous and provoked/traumatic dissections. Improved resolution of noninvasive imaging, namely magnetic resonance angiography (MRA) and computed tomography (CT) angiography (CTA), has increased the number of VADs identified, yet the overall incidence still appears to favor ICAD by  $\approx 2:1$ .<sup>8</sup> A recent study in a large single Finnish center of 301 patients, however, found no difference in the incidence of ICADs compared with VADs.<sup>160</sup>

Dissections thought to be associated with CMT, however, have a clear VA predominance. In fact, early reports have suggested that ICADs associated with CMT are either very rare or nonexistent. An approximate 3:1 predominance of VADs over ICADs in those associated with CMT fits with other analyses.<sup>161</sup> Moreover, multiple vessel dissection is not rare, being present in  $\approx 10\%$  to  $15\%$  of cases.<sup>2,6,8,9,11,160</sup> Multiple cervical vessel involvement of dissections has been reported after CMT, including simultaneous VA and ICA involvement.<sup>162</sup>

### Clinical Presentation

With the increasing use of noninvasive imaging, CD is being diagnosed in many patients who present with subtle manifestations.<sup>90,159,163–170</sup> Most patients have at least 2 symptoms, although symptoms may occur in isolation and some CDs remain asymptomatic. Localized warning symptoms and signs are common and provide an opportunity to recognize and treat patients before cerebral ischemia occurs. Asymptomatic CDs are frequently encountered especially when investigating clinically symptomatic ones. This makes most estimates of the frequency of symptoms in CDs probable overestimates.

### Dissection of the ICA

The typical patient with ICAD presents with pain on one side of the head, face, or neck accompanied by a partial Horner syndrome and followed hours or days later by cerebral or retinal ischemia. This classic triad of pain, Horner syndrome, and ischemia is found in fewer than one third of patients.

Pain is usually the initial manifestation of CDs. It is localized on one side of the upper anterolateral neck in one fourth of patients.<sup>90,169</sup> Persistent, isolated neck pain may mimic idiopathic carotidynia if it is associated with local tenderness. Unilateral facial, dental, or orbital pain is present in half of the patients.<sup>169</sup> The extracranial pain remains isolated in  $\approx 10\%$  of patients, but usually there is an ipsilateral headache.<sup>169</sup> The

characteristic unilateral headache develops in two thirds of patients, most commonly in the frontotemporal area, but it occasionally involves the entire hemicranium or the occipital area.<sup>169</sup> The onset of headache is usually gradual, but it may be a “thunderclap” headache that mimics an SAH.<sup>90,169</sup> The severity of the headache is variable. It is most commonly described as a constant steady aching, but it may also be throbbing or steady and sharp.<sup>169</sup> About one fourth of patients with a history of migraine consider the headache to resemble a migraine, but most patients consider the headache or facial pain to be unlike any other pain.<sup>90,169</sup> After the onset of pain, the median time to the appearance of neurological symptoms is on average 9 days (range, 1–90 days).<sup>169</sup>

Horner syndrome has long been recognized as a manifestation of ICAD, but it is found in fewer than half of the patients.<sup>90,167,169</sup> Facial anhidrosis is not present because the facial sweat glands are innervated by the sympathetic plexus surrounding the external carotid artery. Oculosympathetic palsy associated with severe orbital pain may mimic a cluster headache. Even in the absence of any other sign or symptom, unilateral Horner syndrome should be considered to be caused by an ICAD until proven otherwise.

Cranial nerve palsies can be detected in  $\approx 12\%$  of patients with ICAD.<sup>168</sup> The lower cranial nerves are the most commonly affected, particularly the hypoglossal nerve. Involvement of various combinations of cranial nerves has been described.<sup>168</sup> The oculomotor, trigeminal, and facial nerves also may be involved.<sup>168</sup> Impairment of taste (dysgeusia) may be the presenting symptom and is eventually noted by 10% of patients.<sup>169</sup> The combination of dysfunction of lower cranial nerves and Horner syndrome may be ascribed erroneously to a brainstem infarct. Pulsatile tinnitus is reported by one fourth of patients, and an objective bruit may be present on auscultation.

Cerebral or retinal ischemic symptoms are reported in 50% to 95% of patients with ICADs, although this frequency has decreased over the years because the condition is diagnosed in more patients with less obvious manifestations.<sup>90,168,169</sup> Permanent blindness as a result of ischemic optic neuropathy or occlusion of the central retinal artery or its branches is rare.

### Dissection of the VA

The typical patient with VAD presents with pain in the back of the neck or head followed by posterior circulation ischemia. The first manifestations of VAD, however, are less distinct than those of ICAD and usually are initially interpreted as musculoskeletal in nature.<sup>169</sup> Pain develops in the back of the neck in half of the patients, and a headache occurs in two thirds of the patients, almost always in the occipital area, but in rare cases it involves the entire hemicranium or the frontal area.<sup>169</sup> The neck pain or headache can be bilateral.<sup>169</sup> When it is unilateral, it is always ipsilateral to the dissected VA.<sup>170</sup> The headache may be throbbing in quality or steady and sharp. Only half of the patients consider the neck pain or headache to be unlike any other, but it is rarely mistaken for a migraine attack by those with a history of migraine. The median interval between the onset of neck pain and the appearance of other symptoms is  $\approx 2$  weeks.<sup>169</sup> Unilateral pain or weakness of an arm as a result of cervical root involvement, usually at

the C5–C6 level, and spinal epidural hematomas are unusual manifestations of VADs.<sup>159,163,166</sup>

Ischemic symptoms occur in most patients in whom a VAD is diagnosed and may involve the brainstem, particularly the lateral medulla (Wallenberg syndrome), as well as the thalamus, temporo-occipital regions, or cerebellar hemispheres.<sup>159,163,167,169</sup> Isolated ischemia of the cervical spinal cord is an uncommon but increasingly recognized complication of VAD. Transient ischemic attacks are less frequent after VADs than after ICADs.<sup>169</sup> SAH is uncommon and seen only with intracranial dissections (57% versus 0%;  $P=0.003$ ).<sup>171,172</sup>

### Pathology

In CDs, typically an intimal defect occurs and allows passage of blood into the arterial wall. An intramural hematoma (false lumen) propagates within the tunica media for variable distances. Less commonly, there is no communication between the true and false lumens, suggesting that the dissection was the result of a primary intramedial hematoma. In either case, one of several consequences may arise. An elongated intramural hematoma may form and compress the true lumen to one side, forming an elongated irregular stenosis or narrowing of the true lumen. In extreme cases, the elongated narrowing may be extraordinarily severe and pathologically result in an occlusion or the angiographic appearance of a “string sign” (ie, near occlusion). Proximally, these stenoses have a tapered appearance; distally, the lumen may be abruptly reconstituted. A very large intramural hematoma may compress and occlude the arterial lumen. The pathological profile results in the angiographic appearance of a tapered occlusion resembling a candle flame. The false lumen may reconnect with the true lumen distally, creating parallel channels of a “double-barreled gun.” The 2 channels are separated by an elongated intimal flap. The intramural hematoma may expand outward toward the adventitia to create an aneurysmal sac or dissecting aneurysm. These aneurysms may harbor thrombi.<sup>1,11,163,173–177</sup> (Figures 1–3).

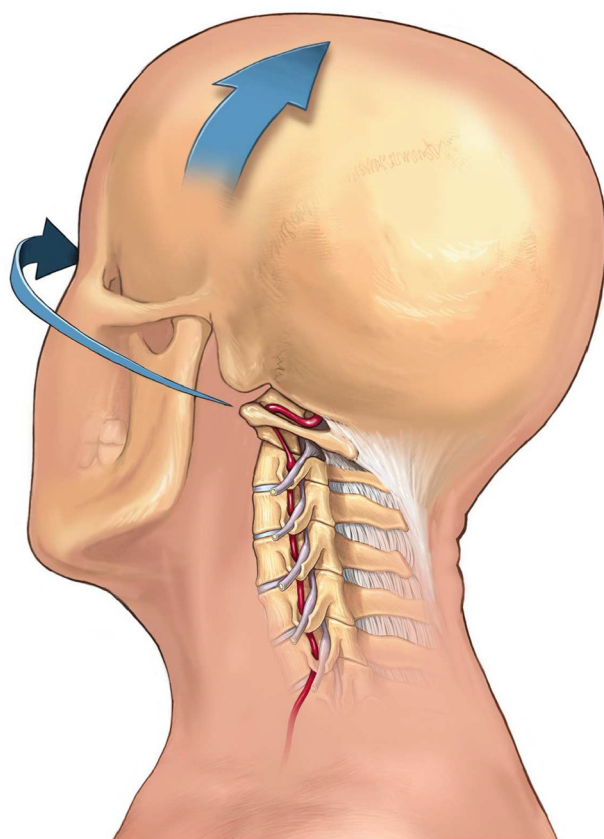
The intramural hematoma is located within the layers of the tunica media but may be eccentric and directed toward the intima (subintimal dissection) or toward the adventitia (subadventitial dissection).<sup>26,178</sup> The absence of an external elastic lamina and a thinner adventitia results in intracranial arteries being prone to subadventitial dissection and resultant SAH, reported more commonly in intracranial VADs.<sup>5,171,172,179–184</sup>

Histological studies of CDs typically show tearing in the intima and media and hemorrhagic dissection within the outer layers of the tunica media, which may result in severe stenosis. The dissection tract typically contains fibrovascular granulation tissue with collections of red blood cells, fibrin, proliferating fibroblasts, early neovascularization changes, and hemosiderin-containing macrophages.<sup>27</sup>

### Diagnosis and Investigations

The diagnosis of CD rests on a careful clinical history, physical examination, and targeted ancillary investigations (Table 3). The probability of CD as a stroke mechanism is greater in younger patients without vascular risk factors who are less likely to have cerebrovascular atherosclerosis. Other



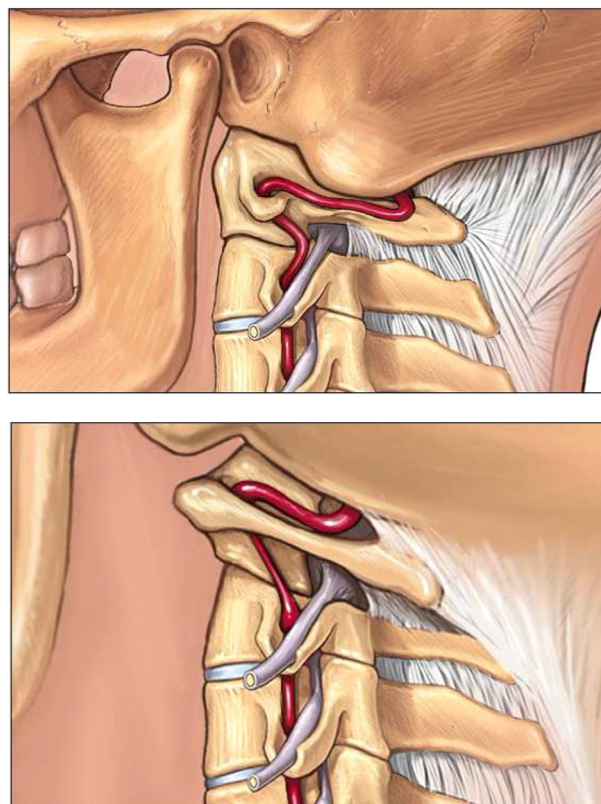


**Figure 1.** The vertebral artery as it passes through the transverse foramina of C6 through C2 and then enters the skull base through the foramen magnum (not shown). **Arrows** indicate head movement during lateral rotation and lateral flexion. Flexion, extension, and traction may also affect the artery (not shown). Reprinted with permission. Copyright © 2013 Trial FX.

clinical features that may be risk factors for CD were mentioned previously.

Even before specific radiological tests are ordered, some assessment of the pretest probability of dissection should be made. The demographics of the individual patient, especially age (usually young), conventional vascular risk factors (usually absent), and the presence of other symptoms mentioned above should raise the consideration of a diagnosis of CD.

Imaging of the arterial wall has been emphasized recently rather than imaging of the secondary consequences of the dissection: luminal compromise, dissecting aneurysm formation, an intimal flap, and resultant stroke. Although these secondary consequences are common, they are not universal; reliance on them can lead to missed diagnoses. When the relative sensitivities of these imaging modalities are being interpreted, the comparators need to be considered carefully. Some studies of VAD, for example, explicitly excluded subjects unless there was an imaging abnormality.<sup>10</sup> This will tend to decrease the overall population with dissection and thus increase the reported sensitivity of a test. An ongoing international study defines the typical radiological appearance of CD or VAD as “mural hematoma, pseudoaneurysm, long tapering stenosis, intimal flap, double lumen, or occlusion >2 cm above the carotid bifurcation demonstrating a



**Figure 2.** Schematic diagram illustrating the neutral anatomic alignment of the vertebral artery (**top**) and stretching of the V3 segment during lateral rotation and lateral flexion (**bottom**). Reprinted with permission. Copyright © 2013 Trial FX.

pseudoaneurysm or a long tapering stenosis after recanalization.”<sup>19</sup> The imaging modalities that are available to detect these abnormalities are duplex ultrasonography, CT, CTA, magnetic resonance imaging (MRI), MRA, and digital subtraction angiography (DSA).

Studies have been hampered by the absence of a gold standard given that no imaging test is flawless and that false-negative studies are possible with all modalities. A reference standard, that is, neurological diagnosis of CD, may need to be considered in diagnostic research,<sup>29</sup> which is more in line with clinical practice.

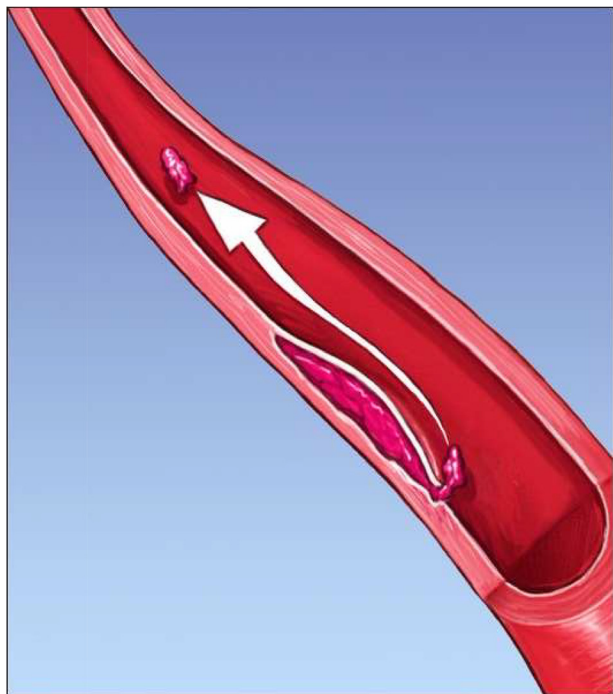
MRI with diffusion-weighted imaging is clearly more sensitive than CT for acute infarcts,<sup>185</sup> especially if they are small and in the posterior circulation. Most strokes caused by CD are embolic as opposed to hemodynamic<sup>28</sup> and are not necessarily related to the degree of arterial stenosis in the dissected vessel.<sup>29,30</sup>

### Duplex Ultrasonography

Ultrasonography has the advantages of being noninvasive, inexpensive, and widely available. Ionizing radiation is not used, and there are few, if any, contraindications. The direct signs of CD on ultrasonogram are stenosis (increased velocities), occlusion, echolucent vessel hematoma, or double lumen. The indirect signs are increased or decreased pulsatility and collateral or retrograde flow.<sup>31</sup>

In CD, the sensitivity of ultrasonography depends on the severity of the stenosis. In severe stenosis or occlusion, it





**Figure 3.** Thrombus from a nonocclusive dissection becoming dislodged and embolizing downstream. Reprinted with permission. Copyright © 2013 Trial FX.

is 100% sensitive, but the sensitivity falls to 40% when the stenosis is only mild.<sup>32</sup> One study found abnormalities on color-flow Doppler in 100% of VADs.<sup>100</sup> Others have found abnormalities on ultrasonogram in 29 of 31 VADs<sup>31</sup> and 24 of 26 VADs.<sup>186</sup> VADs that were normal on ultrasonogram were nonocclusive.<sup>31</sup> In ICADs presenting only with a Horner syndrome, ultrasonogram was abnormal in only 69%.<sup>187</sup>

The technical expertise needed to identify the more subtle ultrasonographic findings of VAD is an important factor that limits its use. Other disadvantages include the difficulty in distinguishing stenosis secondary to atherosclerosis from dissection, the overestimation of subtotal stenosis as occlusion, its limited intracranial access, and a decreased sensitivity for detecting an expansion of wall thickness and small tears. In routine practice, ultrasonography is used less commonly than CT, MR, or DSA but may be considered an alternative if other anatomic imaging is not available.

### CT and CTA

The advantages of CTA include excellent spatial resolution, very rapid acquisition, widespread availability, noninvasiveness, and lower cost compared with MRI and DSA. Although not universally agreed on, a study that assessed radiologists' preferences for imaging studies done in routine practice suggested a preference for CTA over MRI in VAD but equivalence for CD.<sup>188</sup> In this study, there were no CTA false-positives for occlusion. Vessel wall irregularity was seen in 24 of 25 dissected arteries; 4 pseudoaneurysms and 8 intimal flaps were detected that were missed with MRA; and vessel wall thickening was detected in 96%. Lum and colleagues<sup>189</sup> defined the suboccipital rind sign as dorsal thickening of the arterial wall against the adjacent fat in the V3 section of the

VA. In patients with VAD, the arterial wall was significantly thicker by  $\approx 3$  mm compared with that in normal controls with no difference in luminal diameter. This finding is not specific for dissection, as it can be seen in giant cell arteritis.<sup>190</sup> All VADs were associated with an increased external vessel diameter on CT.

Contraindications to CTA include impaired renal function, contrast allergy, and pregnancy. In addition, CT entails exposure to radiation, and CT is much less sensitive for brain infarction than MRI, especially in the posterior fossa.

### MRI/MRA

One of the major advantages of MRI for VAD is the associated benefit of highly sensitive diffusion-weighted sequences for detection of parenchymal infarction. MRA, especially with contrast enhancement, has excellent spatial resolution and is not as affected by bony artifact as CTA. This is highly relevant in the V3 and V4 segments of the VA and in the ICA as the artery enters the skull base. MRI of the soft tissue of the neck using axial T1-weighted fat-suppressed images, which are not usually part of a routine MRI, can detect the methemoglobin of the intramural hematoma. The hematoma is initially isointense on T1 and T2, then hyperintense on T1, and later hyperintense on T2. It is eccentrically located; may appear curvilinear, crescentic, or simply adjacent to the lumen; and may enhance slightly. The arterial diameter should widen on the soft tissue imaging. Any of these changes can persist for months and then normalize.<sup>191</sup> Any of these findings are better established in the ICA than in the VA, which is smaller and surrounded by an epidural venous plexus with similar, but not identical, characteristics.<sup>58</sup> Newer high-resolution MRI may be able to distinguish between the surrounding perivertebral venous plexus and the crescent signal intensity changes of a mural hematoma.<sup>29</sup>

Contraindications and limitations of MRI/MRA include older pacemakers and other implanted metal, cost, prolonged scanning time, claustrophobia, body habitus, and susceptibility to motion artifacts. The specific limitations for MRI in VAD include the tortuous course of the artery, variability in normal vessel caliber and frequent asymmetries, the small size of the mural hematoma, and the potential pitfalls caused by the adjacent perivertebral venous plexus.<sup>29</sup>

### Digital Subtraction Angiography

The gold standard for luminal imaging has long been conventional DSA. The frequent association of luminal abnormalities with VAD has led many to consider this imaging modality to have the highest positive and negative predictive values. However, imaging of the arterial wall with the newer ultrasonography, CT, and MRI techniques described above has demonstrated that DSA can be falsely negative in as many as 17%.<sup>173</sup> The common DSA signs of dissection are pseudoaneurysm ( $\approx 5\%$ ),<sup>10</sup> usually ovoid, parallel to the lumen, and variable in size; an intimal flap ( $<10\%$ ),<sup>191</sup> that is, elevation of the intima from the arterial wall; double lumen, that is, a channel of blood parallel to the native lumen (rare)<sup>192</sup>; and a smooth or irregular tapering ( $66\%$ )<sup>10</sup> or occlusion ( $28\%$ ).<sup>10</sup>

**Table 3. Diagnostic Conclusions**


---

Diagnosis of CD should be suspected in patients with an appropriate clinical syndrome, especially when patients are young and without conventional cerebrovascular risk factors.
Diagnosis of CD is supported by the absence of radiological findings typical for other cerebral arteriopathies (eg, atherosclerotic cerebrovascular disease).
No single test must be viewed as a gold standard.
Imaging of the arterial wall is advisable.
Repeat imaging studies over time are often required.

---

CD indicates cervical artery dissection.

Disadvantages of DSA include the time, expense, required technical expertise, need for contrast administration, and procedural complications, which are rare (<1%) but potentially severe (eg, stroke). The wide availability of sensitive, high-quality noninvasive imaging at referral centers, in conjunction with the potential for procedural complications with DSA, has limited the use of DSA for solely diagnostic purposes. If an intervention is needed or in those instances when diagnosis remains ambiguous and treatment decisions will be altered by the findings, then DSA is considered.

### Follow-Up Imaging

Follow-up imaging may be needed to confirm retrospectively the presumed CD diagnosis. Atherosclerotic stenoses are unlikely to recanalize or to improve with time, whereas an improvement in vessel caliber on follow-up imaging is common in CD.

The European Federation of Neurological Societies has concluded that MRI should be the initial imaging procedure,<sup>193</sup> but we suggest that no single test should be seen as the gold standard. In particular, brain tissue itself can be assessed with MRI for small or subtle infarction that would go undetected on head CT. MRA should be ordered for both the intracranial and extracranial circulation. CTA has high resolution for detecting CD, particularly those involving the VAs. Multiple complementary tests, often repeated and compared over time, may be needed for an accurate diagnosis and treatment planning.

### Treatment of CDs

A systematic review of the literature found no randomized trials that specifically evaluated the treatment of CD associated with CMT or CDs related to any other origin. Most reports on treatment are part of case series encompassing a variety of causes in which CMT-associated dissections are also included. Because the pathophysiological mechanisms leading to thrombosis and embolism are presumably similar, it stands to reason that no distinction should be made in the selection of treatment of the acute event or for subsequent prevention strategies. Treatment of ICAD and VAD is similar for the most part. However, dissections of the intradural portion of the VA have a great chance of tearing through the subadventitia, leading to SAH, which may cause a sudden fatal outcome. Moreover, those patients with extracranial VAD with intracranial extension or with intracranial vertebrobasilar artery dissection presenting with SAH have a high incidence of rebleeding, often in the first 24 hours. In such patients and under some circumstances, endovascular or surgical intervention, in addition to

limiting the use of antithrombotic agents, particularly among those with aneurysmatic intracranial vertebrobasilar artery dissection, may be considered.<sup>171,172,179,194–202</sup>

Treatment can be categorized as acute management and secondary prevention. Acutely, treatment is focused on the re-establishment of blood flow to brain tissue at risk. Specific strategies include those that can be used for ischemic stroke from other causes, namely thrombolysis with tissue-type plasminogen activator, and, under some circumstances, endovascular therapies using a variety of techniques. Anticoagulants and antiplatelet agents are generally used to prevent early and late stroke recurrence. As for other causes of ischemic stroke, secondary stroke prevention recommendations should be followed when applicable.<sup>203</sup>

### Acute Management

#### Endovascular Treatment

There are no randomized trials of endovascular treatment in patients with CDs associated with CMT or any other causes.<sup>165,194</sup> Several case reports document the success of endovascular intervention to reestablish blood flow in patients with severe stenosis or occlusion at the site of the CD.<sup>66,204–206</sup> A recent systematic review of stenting reported the results in 140 patients with ICADs (16% iatrogenic) and 8 patients with VADs (20% iatrogenic).<sup>207</sup> Failure of medical management and contraindication to anticoagulation use were the most common indications for endovascular treatment. Procedural complications and recurrent strokes were uncommon.<sup>207</sup> However, it remains unproven that endovascular treatments improve CD outcomes, and the long-term complications from stenting in patients with CDs are not known.

#### Thrombolysis

There has been theoretical concern that thrombolysis with tissue-type plasminogen activators could worsen the dissection and patient outcome. This has been noted in rare instances<sup>208</sup> and is unlikely to be common. Thrombolysis with tissue-type plasminogen activator appears to be safe in patients with acute ischemic stroke secondary to CD. A recent meta-analysis of 180 patients with CD and acute stroke did not show any increase in complications, including intracranial hemorrhage, when outcome in thrombolized patients was compared with that of control subjects from the Safe Implementation of Thrombolysis in Stroke–International Stroke Thrombolysis Register (SITS-ISTR).<sup>209</sup> In another study of thrombolysis in 488 patients with acute stroke secondary to CD in the United States between 2005 and 2008, there was no increase in the risk of intracranial hemorrhage compared with patients without arterial dissection.<sup>210</sup> Patients in whom CMT was associated with the CD were not reviewed separately in either report.

### Prevention of Stroke Recurrence

#### Antithrombotic Therapy

There are no randomized trials of early or long-term antithrombotic therapy in CD. The Cervical Artery Dissection in Stroke Study (CADISS) is an ongoing study determining the feasibility of a clinical trial comparing antiplatelet therapy with anticoagulants in the acute treatment of patients (≥18 years

of age) with extracranial CD (ICAD or VAD) with symptom onset within 7 days.<sup>211</sup> Antiplatelet and anticoagulant treatments are used for both the prevention of local thrombus propagation and secondary embolism. The Cochrane systematic meta-analysis of nonrandomized studies is a useful resource on outcomes with antiplatelet agents versus anticoagulants.<sup>194</sup> Comparison across 36 observational studies (1285 patients) showed no difference in the rates of subsequent stroke or death between the 2 treatment modalities. Few studies have reported treatment in patients with CD associated with cervical manipulation. In the largest case series from Germany, 35 of 36 patients with VAD were treated with intravenous heparin for 12 days. This was followed by oral warfarin for 6 to 12 months in 31 of 36 patients and aspirin in 3 patients.<sup>101</sup>

In a United Kingdom-based survey, CDs were always treated with anticoagulants by 50% of the physicians, 30% of physicians always used antiplatelets, and 15% used either anticoagulants or antiplatelets.<sup>212</sup> A meta-analysis showed no advantage of anticoagulants compared with aspirin for the primary outcome measures of death or disability.<sup>213</sup> The choice of an antiplatelet or anticoagulant is empirical and is often determined by the treating physician's experience and personal preference. Antiplatelet treatment is preferred in certain scenarios such as in patients with large cerebral or cerebellar infarctions, in those with intracranial extension of dissections, or when anticoagulation is contraindicated.<sup>165</sup> Similarly, some physicians may prefer anticoagulation over antiplatelets in the presence of a severe underlying arterial stenosis in the dissected vessel, thrombus in the arterial lumen, or pseudoaneurysm formation.<sup>165</sup>

The optimal duration for antithrombotic therapy has not been well studied. If anticoagulant therapy is used, it is generally discontinued after 3 to 6 months of treatment. Arterial recanalization/remodeling, if it is to occur, is generally complete by 6 months. It is unclear whether antiplatelet agents warrant long-term continuation, especially in spontaneous CD with no clinical evidence of an underlying connective tissue disorder. Long-term antiplatelet treatment may be considered in the setting of residual arterial stenosis, vessel wall irregularity, or persistent occlusion despite the lack of evidence for a high risk of recurrence of stroke in such situations.<sup>165</sup> Patients with underlying connective tissue disorder, a history of recurrent CD, or a family history of CDs should probably be maintained on indefinite antiplatelet therapy. Which antiplatelet is best also remains undetermined. Aspirin is the most commonly used agent in antiplatelet-naïve patients (75–100 mg/d).<sup>214</sup> Recommendations for the treatment of hypertension and the use of oral contraceptive pills or hormone replacement therapy among patients who have had an ischemic stroke resulting from CD should be followed according to other AHA guidelines on secondary stroke prevention.<sup>203</sup> Women with CD who are taking oral contraceptive pills or hormone replacement therapy should discontinue them as part of their treatment. There is no indication for statin use in the typical CD population without known high-risk cardiovascular risk factors. Our management conclusions are summarized in Table 4.

### Outcome and Prognosis

The outcomes and prognoses in patients with CD can be divided into clinical outcomes (after recovery from initial

presentation), long-term status of the dissected arteries, and risk of recurrence of CD or cerebral ischemia. Overall, there is limited information about outcomes and prognosis focused specifically on patients whose CD may have been associated with CMT. Outcomes and prognoses are thus described for mostly spontaneous CDs (although many case series did not separate out traumatic cases), and when possible, specific mentions of those cases associated with CMT are highlighted.

### Clinical Outcomes

Early reports suggested very poor outcomes from CD, but they were likely for a highly selective group identified in the preangiography era. As noninvasive testing has become more sensitive and commonly performed, more patients are being identified with CDs with less severe symptoms, and outcomes among modern CD cohorts are accordingly better.<sup>1,215</sup> Overall, death from ICAD or VAD is thought to be  $\leq 5\%$ .<sup>1,2,59,98,160</sup> Even in an older series of 200 consecutive patients with spontaneous CD from 1970 through 1990 seen at the Mayo Clinic, the 10-year survival rate was 95.5%, with only 2 patient deaths likely related to dissection.<sup>11</sup>

Good or favorable outcome is most commonly defined as follow-up modified Rankin Scale (mRS) scores of either 0 to 1 (little or no residual disability) or 0 to 2 (includes slight disability). In general, the majority of patients with strokes caused by CDs have good outcomes, with rates that vary from 70% to 92%.<sup>8,59,98,160,215–220</sup> Even a small series of 12 cases with 3 or 4 simultaneous dissections on initial diagnosis from 3 European centers showed excellent outcomes (mRS score=0–1) in 83%.<sup>221</sup> Associations with better outcomes include ICAD that had shown recanalization<sup>215</sup> and lesser initial stroke severity.<sup>59,160,215,222</sup> Associations with worse outcomes include bilateral VADs,<sup>216</sup> dissected arterial occlusion (versus stenosis),<sup>98,160,219</sup> ICA versus VAD,<sup>222,223</sup> and older age.<sup>16</sup> Despite the largely good outcomes, ICAD is a possible potential cause of malignant middle cerebral artery syndrome in young patients.<sup>224</sup>

A case-control study from Bern and Zurich in Switzerland matched 46 ICAD cases with severe stenosis or occlusion at 1 year to 46 controls with only transient arterial stenosis or occlusion, arguing against persisting severe stenosis or occlusion as a risk factor for poor outcome. Stroke severity at the 3-month follow-up was not significantly different between groups. Most patients presented with stroke in both groups; 29% were disabling (mRS score  $>2$ ) in the persistent stenosis/occlusion group versus 18% in the transient steno-occlusive group.<sup>225</sup>

In a different type of outcome assessment, the clinical outcomes in a series of consecutive nontraumatic CDs (87 ICA, 19 VA, 2 both) from the University Hospital in Bern in Switzerland were assessed not only by mRS score but also by the more patient-centered Stroke Specific Quality of Life (SS-QOL) scale. SS-QOL score was good in 93% of patients before dissection but considerably less at 54% after dissection. After a mean follow-up of 4 years, the mRS score was 0 to 1 in 72%. There was a high correlation between the mRS and the SS-QOL; however, 30% of patients with little or no disability (mRS score=0–1) had poor ratings on the SS-QOL. Predictors of poor quality of life were higher National Institutes of Health Stroke Scale scores at diagnosis and older age. These findings suggest that the mRS may underestimate the impact of CD on



**Table 4. Management Conclusions for Extracranial CD**

Thrombolysis with intravenous tPA is reasonably safe in the treatment of patients with acute ischemic stroke caused by CD within 4.5 h.

For patients with TIA or ischemic stroke resulting from CD, antiplatelets or anticoagulant therapy for 3–6 mo is reasonable.

Endovascular therapy may be considered for patients with CD who experience definite recurrent cerebral ischemic events while on appropriate antithrombotic therapy.

CD indicates cervical artery dissection; TIA, transient ischemic attack; and tPA, tissue-type plasminogen activator.

quality of life and that additional or alternative outcome measures may better capture patient-centered effects.<sup>226</sup>

A recent series that included 66 stroke patients from Italy with ICADs and complete occlusion used transcranial Doppler to evaluate the role of collateral circulation on clinical outcomes. When considering the main intracranial arterial collaterals (ophthalmic, anterior communicating, posterior communicating), patients with  $\geq 2$  such collaterals present had lower initial National Institutes of Health Stroke Scale score and only 5% had mRS scores  $>1$  at 90 days compared with 77% with mRS scores  $>1$  among those with  $\leq 1$  collateral.<sup>227</sup>

Some of the CD case series have commented on the proportion of cases associated with recent CMT. A series of 27 dissections from a stroke service in Arizona described 85% of patients having no or only minor disability. The remainder (15%) had moderate disability at a mean follow-up of 58 months. Two of the 5 “traumatic” CDs included were VADs and were ascribed to CMT. However, associations with outcomes in these 2 patients were not reported separately.<sup>217</sup> A series of 126 patients from a single hospital in Münster, Germany, included ICADs and VADs; CMT was a risk factor in 16% of cases. After a maximum of 6 months of follow-up, 70% had an excellent recovery, 17% had mild to moderate disability, 12% had severe disability, and 1 patient died. In a multivariate analysis, arterial occlusion and stroke were predictive of poor outcome, whereas associated CMT was not.<sup>98</sup> A 2003 report from the Canadian Stroke Consortium included 116 patients (49 ICA and 67 VADs); 17% of cases were associated with CMT. Of the 90% available for the 1-year follow-up, 89% had good outcome (mRS score=0–2). However, CMT was not mentioned as being associated with clinical outcome.<sup>218</sup> A series of 177 CD patients (211 dissected arteries: 118 ICAs and 93 VAs) from Stanford included 19 who had recent CMT and 8 associated with self-manipulation of the neck. Four patients (2.3%) died, 3 of the 4 patients as a result of the initial stroke. Again, CMT was not mentioned as it relates to outcome.<sup>2</sup>

An early series limited to cases thought to be a result of CMT described 4 patients from Hamburg, Germany. All 4 patients had VADs, 2 were bilateral and 1 was associated with an ipsilateral ICAD. All patients improved clinically after presentation, with 1 of the 4 having no residual deficits.<sup>228</sup> In 2006, a series of 36 VADs associated with chiropractic therapy of the neck were reported from 13 German academic neurology departments. At hospital discharge, 73% had a good outcome (mRS score=0–2), 1 patient died, and another remained in a vegetative state. The authors questioned whether these VADs after cervical manipulation had a worse prognosis than those otherwise considered to be spontaneous. In this retrospective clinical survey, orthopedic

surgeons conducted the neck manipulation in half of the subjects. Complications also occurred when the manipulation was carried by neurologists, chiropractors, or general practitioners.<sup>101</sup> A recent report from the Barrow Neurologic Institute in Phoenix, AZ, described the clinical course and outcomes of 13 patients with presumptively CMT-associated CDs. Most involved the VA, and 9 of 13 (69%) had excellent outcomes. Six patients had endovascular interventions, including 5 with stents placed and 1 who underwent basilar artery thrombolysis. Three cases required emergent cerebellar decompression for edematous infarction-related mass effect (all were left with permanent disability), and 1 patient died. The authors suggest that although most patients have good outcomes, serious neurological injury is not uncommon, may require aggressive interventions, and can lead to poor outcomes.<sup>66</sup> These data, however, may represent a biased referral sample of severe cases.

Overall, the clear majority of patients with CDs have good outcomes as measured by the mRS, although possibly less so if one instead focuses on quality of life. A number of factors such as higher initial stroke severity and arterial occlusions have been repeatedly associated with worse clinical outcomes; collaterals also likely play a role. From the limited information available, we cannot make any statements about possible differential outcomes among CD patients associated with CMT.

### Follow-Up of Dissected Arteries

Many of the case series of CDs have described improvements in arterial patency on follow-up imaging. Estimates of overall recovery of arterial patency range from 55% to 78%.<sup>2,217,222,223,225,227</sup> Factors associated with increased chances of recanalization include spontaneous (versus traumatic) dissections,<sup>229</sup> stenotic vessels (versus occluded vessels),<sup>1,2,160,215,221</sup> dissections in women,<sup>2</sup> and VADs versus ICADs.<sup>223</sup> Factors associated with lack of recanalization were smoking and older age.<sup>163</sup> A factor specifically identified as not affecting recanalization rate was type of antithrombotic therapy.<sup>215</sup> Generally, neurological outcome depends on lesion localization and the presence of adequate collaterals.<sup>230</sup>

Approximately 10% to 50% of CDs are associated with extracranial dissecting aneurysms.<sup>65</sup> A French series of 16 patients with ICAD aneurysms provided routine follow-up imaging data for an average of 37 months. Of 20 aneurysms, 13 remained unchanged, 1 had resolved, 6 had decreased in size, and none had ruptured.<sup>231</sup> A second series of dissecting aneurysms from Paris, France, included 35 of 71 dissections (49%) with aneurysmal dilatation; these were more commonly seen in patients with multiple arteries dissected. Over a span of 37 months of follow-up, 22 of 33 patients had at least 1 aneurysm remaining. For 22 ICADs that were symptomatic and had aneurysms, 46% were unchanged, 18% had decreased in size, and 36% resolved. Resolution was significantly more common for VAs (83%). There was no history or imaging to suggest that any of the aneurysms had ruptured.<sup>65</sup> A subset of 279 dissections from Bern and Zurich included 38 patients (14%) with 42 dissection-related aneurysms; 23 of the 42 aneurysms (55%) were detected on a first angiogram and the remainder on follow-up angiograms at an average of 9 months later. No change in morphology was noted in 12 patients with

angiographic follow-up. Clinical follow-up of all patients for an average of 6.5 years demonstrated 3 ischemic strokes, all without evidence of aneurysm rupture or as the clear cause of ischemia.<sup>232</sup> Overall, dissection-related extracranial cervical artery aneurysms seem to have a benign prognosis, with little evidence of causing later ischemia and virtually never rupturing. No reports commented on any association with CMT.

The timing of recanalization of dissected cervical arteries is also of interest because it may guide decisions about duration of antithrombotic therapy. Case series comment that recanalization often occurs within the first 6 months or earlier,<sup>1,215,220</sup> that 82% of healing occurs within the first year with a median time to healing of 3 to 4 months,<sup>8</sup> and that median time until near or total recanalization was 4.7 months.<sup>2</sup> Again, no reports commented on any association with CMT.

### Risk of Dissection or Stroke Recurrence

Asymptomatic dissection recurrence could be identified only in series in which routine imaging follow-up was performed.

In the 200 spontaneous CDs series from the Mayo Clinic, the cumulative rate of dissection recurrence was 2% in the first month, 3.7% over 2 years, 5% over 5 years, and 11.9% over 10 years. The recurrence was symptomatic in almost all patients, with younger patients at relatively increased risk of recurrence. All of the recurrent dissections occurred in different cervical vessels.<sup>11</sup> Table 5 shows many other cohorts in which rates of recurrence of dissection or stroke were estimated. Overall, the rates of both events were low, with the possibility of ischemic stroke recurrences early after the initial dissection diagnosis.

In a prospective MRI series from Muenster, Germany, 6% of patients with CDs had polyarterial involvement on initial MR, and 9 additional patients (25%) had recurrent dissection in another artery, 7 of those 9 in the first 4 weeks. The higher rate of recurrent dissections compared with older studies was hypothesized to be a result of the prospective follow-up (versus symptom triggered) with sensitive MRI. MRI-identified recurrent dissections were asymptomatic in 8 of 9 patients

**Table 5. Reports of Recurrent Stroke or Recurrent Dissection in Patients With Dissection**

Author	Method	Population	Recurrence Risk Comments
Bassetti et al, <sup>233</sup> 1996	Single-center, prospective cohort	81 Consecutive patients with CD	All surviving patients had repeat clinical and ultrasonographic examinations; 3 of 74 patients (4%) had recurrent ICAD over ~3 y
Guillon et al, <sup>231</sup> 1999	Single-center, retrospective cohort	16 Patients with 20 ICA dissecting aneurysms	No aneurysm worsening and no recurrent strokes over mean of 37 mo
Touze et al, <sup>65</sup> 2001	Single-center, prospective cohort	35 Patients with ICA or VA dissecting aneurysms	No aneurysm worsening and no recurrent strokes over mean of 42 mo
Dziewas et al, <sup>98</sup> 2003	Single-center, retrospective cohort	126 Consecutive patients with CD	Recurrent CD in 4 patients (3.2%) in the first month, and an additional 2 patients (1.6%) from 1 mo–1 y
Kremer et al, <sup>225</sup> 2003	2-Center, prospective, nested, case-control study	92 Patients with either persistent (cases) or transient (controls) severe ICA stenosis or occlusion caused by dissection (at a 1-y follow-up ultrasonographic examination)	Risk of subsequent stroke was 1.4%/y for cases (average follow-up, 6.2 y) and 0.6%/y for controls (average follow-up, 7.2 y)
Beletsky et al, <sup>218</sup> 2003	Multicenter, prospective cohort	116 Patients with CD	Recurrent events occurred in 9 of 105 patients followed up for a rate of 10.4%/y; most of these events occurred in the first 2 wk after CD
Touze et al, <sup>234</sup> 2003	Multicenter, retrospective cohort	459 Patients with CD	During a mean follow-up of 31 mo, 4 patients had ischemic stroke and 4 had recurrent CD for rates of 0.3%/y
Lee et al, <sup>8</sup> 2006	Population-based, retrospective cohort	48 Patients with CD	No recurrent CD occurred with a mean follow-up of 7.8 y
Arauz et al, <sup>223</sup> 2006	Single-center, retrospective cohort	130 Patients with CD	6 Patients (4.8%) had recurrent nonfatal ischemic stroke in the first 2 wk after diagnosis; overall recurrence rate was 0.15%/y; average follow-up was 19 mo
de Bray et al, <sup>219</sup> 2007	Single-center, prospective cohort	103 Patients with CD	Annual recurrence rates of stroke of 0.4% and CD of 2% with an average follow-up of 4 y
Georgiadis et al, <sup>235</sup> 2009	2-Center, retrospective cohort	355 Patients with ICA dissection	1 Ischemic stroke (0.3%) occurred during 3 mo of follow-up for each patient.
Metso et al, <sup>160</sup> 2009	Single-center, retrospective cohort	301 Patients with 322 CD	6 (2%) New CDs over 4 y (all in different arteries) and 1 stroke from a new CD
Schwartz et al, <sup>2</sup> 2009	Single-center, retrospective cohort	177 Patients with CD	15 Cases (8.5%) of recurrent ischemic events over a median of 7 mo (about half of these events were in the first 2 wk; 2 patients (1.1%) had recurrent CD
Debette et al, <sup>222</sup> 2011	Multicenter, prospective cohort	982 Patients with CD	19 (2.1%) Patients had recurrent CDs and 18 (2%) had a stroke within 3 mo of diagnosis

CD indicates cervical artery dissection; ICA, internal carotid artery; ICAD, internal carotid artery dissection; and VA, vertebral artery.

(89%); the other patient had a stroke thought to be the result of hemodynamic failure.<sup>236</sup>

Only a few factors have been reported to have an association with an increased risk of recurrence. In an additional report based on the Mayo Clinic cohort, 50% of CDs with a positive family history had recurrence compared with only 6% of those without a positive family history.<sup>38</sup> The large French cohort suggested that having multiple dissections at presentation was the only risk factor identified for later stroke.<sup>234</sup> The de Bray et al<sup>219</sup> series found recurrent symptomatic dissections more commonly in patients with a diagnosis of fibromuscular dysplasia (4 of 17, 24%) compared with those without fibromuscular dysplasia (1 of 82, 1.2%). In the Canadian series, despite 17% of cases potentially associated with neck manipulation, there was no mention of an increased risk of recurrence.<sup>218</sup>

In summary, CD follow-up studies have shown that the risk of recurrent stroke is low and that there may be a higher risk of early recurrent stroke (often from the initially symptomatic dissection) as opposed to late recurrence. Asymptomatic

recurrent CDs seen on MRI are likely more common than symptomatic recurrences, and certain groups (especially those with a family history or flow-mediated dilation) may be at higher risk of recurrence.

## Conclusions

CD is an important cause of ischemic stroke in young and middle-aged patients. CD is most prevalent in the upper cervical spine and can involve the ICA or VA. Disability levels vary among CD patients with many having good outcomes, but serious neurologic injury can occur. Clinical reports suggest that mechanical forces play a role in a considerable number of CDs, and population controlled studies have found an association of unclear etiology between CMT and VAD stroke in young patients. Although the incidence of CD in CMT patients is probably low, and causality difficult to prove, practitioners should both strongly consider the possibility of CD and inform patients of the statistical association between CD and CMT, prior to performing manipulation of the cervical spine.

## Disclosures

### Writing Group Disclosures

Writing Group Member	Employment	Research Grant	Other Research Support	Speakers' Bureau/Honoraria	Expert Witness	Ownership Interest	Consultant/Advisory Board	Other
José Biller	Loyola University Chicago, Stritch School of Medicine	None	None	None	None	None	None	None
Ralph L. Sacco	University of Miami, Miller School of Medicine	None	None	None	None	None	None	None
Felipe C. Albuquerque	Barrow Neurosurgical Associates	None	None	None	None	None	None	None
Bart M. Demaerschalk	Mayo Clinic	None	None	None	None	None	None	None
Pierre Fayad	University of Nebraska Medical Center	AGA Medical*; NINDS*; Yale University*	None	None	None	None	Allergan*	None
Preston H. Long	Evidence-Based Health Services, Inc	None	None	None	None	None	None	None
Lori D. Noorollah	HCA Midwest	None	None	None	None	None	None	Husband is a chiropractor†
Peter D. Panagos	Washington University	None	None	None	None	None	None	None
Wouter I. Schievink	Cedars-Sinai Medical Center	None	None	None	None	None	None	None
Neil E. Schwartz	Stanford University	None	None	None	None	None	None	None
Ashfaq Shuaib	University of Alberta	None	None	None	None	None	None	None
David E. Thaler	Tufts Medical Center	Tufts CTSI grant*; Tufts University "Tufts Collaborates" grant*	None	None	Expert witness testimony in malpractice case†	None	None	None
David L. Tirschwell	University of Washington	None	None	None	None	None	None	None

This table represents the relationships of writing group members that may be perceived as actual or reasonably perceived conflicts of interest as reported on the Disclosure Questionnaire, which all members of the writing group are required to complete and submit. A relationship is considered to be "significant" if (a) the person receives \$10 000 or more during any 12-month period, or 5% or more of the person's gross income; or (b) the person owns 5% or more of the voting stock or share of the entity, or owns \$10 000 or more of the fair market value of the entity. A relationship is considered to be "modest" if it is less than "significant" under the preceding definition.

\*Modest.

†Significant.



## Reviewer Disclosures

Reviewer	Employment	Research Grant	Other Research Support	Speakers' Bureau/Honoraria	Expert Witness	Ownership Interest	Consultant/Advisory Board	Other
Harold Adams	University of Iowa	None	None	None	None	None	None	None
Mitchell Elkind	Columbia University	None	None	None	None	None	None	American Academy of Neurology: associate editor of <i>Neurology</i> *
Karen Furie	Rhode Island Hospital	None	None	None	None	None	None	None
Robert Harbaugh	Penn State University	None	None	None	None	None	None	None
Michael Jaff	Massachusetts General Hospital	None	None	None	None	None	None	None
Steven Levine	SUNY Downstate Medical Center	None	None	None	Law firms*	None	None	None
Joshua Willey	Columbia University	None	None	None	None	None	None	None

This table represents the relationships of reviewers that may be perceived as actual or reasonably perceived conflicts of interest as reported on the Disclosure Questionnaire, which all reviewers are required to complete and submit. A relationship is considered to be "significant" if (a) the person receives \$10 000 or more during any 12-month period, or 5% or more of the person's gross income; or (b) the person owns 5% or more of the voting stock or share of the entity, or owns \$10 000 or more of the fair market value of the entity. A relationship is considered to be "modest" if it is less than "significant" under the preceding definition.

\*Modest.

## References

- Schievink WI. Spontaneous dissection of the carotid and vertebral arteries. *N Engl J Med*. 2001;344:898–906.
- Schwartz NE, Vertinsky AT, Hirsch KG, Albers GW. Clinical and radiographic natural history of cervical artery dissections. *J Stroke Cerebrovasc Dis*. 2009;18:416–423.
- Giroud M, Gras P, Dumas R, Becker F. Spontaneous vertebral artery dissection initially revealed by a pain in one upper arm. *Stroke*. 1993;24:480–481.
- Micheli S, Paciaroni M, Corea F, Agnelli G, Zampolini M, Caso V. Cervical artery dissection: emerging risk factors. *Open Neurol J*. 2010;4:50–55.
- Schievink WI, Mokri B, Piepgras DG. Spontaneous dissections of cervicocervical arteries in childhood and adolescence. *Neurology*. 1994;44:1607–1612.
- Arnold M, Kappeler L, Georgiadis D, Berthet K, Keserue B, Bousser MG, Baumgartner RW. Gender differences in spontaneous cervical artery dissection. *Neurology*. 2006;67:1050–1052.
- Deleted in proof.
- Lee VH, Brown RD Jr, Mandrekar JN, Mokri B. Incidence and outcome of cervical artery dissection: a population-based study. *Neurology*. 2006;67:1809–1812.
- Touze E, Gauvrit JY, Moulin T, Meder JF, Bracad S, Mas JL; Multicenter Survey on Natural History of Cervical Artery Dissection. Risk of stroke and recurrent dissection after a cervical artery dissection: a multicenter study. *Neurology*. 2003;61:1347–1351.
- Beletsky V, Nadareishvili Z, Lynch J, Shuaib A, Woolfenden A, Norris JW; Canadian Stroke Consortium. Cervical arterial dissection: time for a therapeutic trial? *Stroke*. 2003;34:2856–2860.
- Schievink WI, Mokri B, O'Fallon WM. Recurrent spontaneous cervical-artery dissection. *N Engl J Med*. 1994;330:393–397.
- Metso AJ, Metso TM, DeBette S, Dallongeville J, Lyrer PA, Pezzini A, Lichy C, Kloss M, Brandt T, Touze E, Southerland AM, Worrall BB, Abboud S, del Zotto E, Leys D, Engelter S, Grond-Ginsbach C, Tatlisumak T; CADISP Group. Gender and cervical artery dissection. *Eur J Neurol*. 2012;19:594–602.
- Biffi WL, Ray CE Jr, Moore EE, Franciose RJ, Aly S, Heyrosa MG, Johnson JL, Burch JM. Treatment-related outcomes from blunt cerebrovascular injuries: importance of routine follow-up arteriography. *Ann Surg*. 2002;235:699–706.
- Caso V, Paciaroni M, Bogousslavsky J. Environmental factors and cervical artery dissection. *Front Neurol Neurosci*. 2005;20:44–53.
- Dittrich R, Rohsach D, Heidbreder A, Heuschmann P, Nassenstein I, Bachmann R, Ringelstein EB, Kühlenbaumer G, Nabavi DG. Mild mechanical traumas are possible risk factors for cervical artery dissection. *Cerebrovasc Dis*. 2007;23:275–281.
- Stein DM, Boswell S, Sliker CW, Lui FY, Scalea TM. Blunt cerebrovascular injuries: does treatment always matter? *J Trauma*. 2009;66:132–143.
- Fusco MR, Harrigan MR. Cerebrovascular dissections: a review, part II: blunt cerebrovascular injury. *Neurosurgery*. 2011;68:517–530.
- DeBette S, Markus HS. The genetics of cervical artery dissection: a systematic review. *Stroke*. 2009;40:e459–e466.
- DeBette S, Metso TM, Pezzini A, Engelter ST, Leys D, Lyrer P, Metso AJ, Brandt T, Kloss M, Lichy C, Hauser I, Touze E, Markus HS, Abboud S, Caso V, Bersano A, Grau A, Altintas A, Amouyel P, Tatlisumak T, Dallongeville J, Grond-Ginsbach C; CADISP Group. CADISP-genetics: an international project searching for genetic risk factors of cervical artery dissections. *Int J Stroke*. 2009;4:224–230.
- Pezzini A, Caso V, Zanferrari C, Del Zotto E, Paciaroni M, Bertolino C, Grassi M, Agnelli G, Padovani A. Arterial hypertension as risk factor for spontaneous cervical artery dissection: a case-control study. *J Neurol Neurosurg Psychiatry*. 2006;77:95–97.
- D'Anglejan-Chatillon J, Ribeiro V, Mas JL, Youl BD, Bousser MG. Migraine: a risk factor for dissection of cervical arteries. *Headache*. 1989;29:560–561.
- Metso TM, Tatlisumak T, DeBette S, Dallongeville J, Engelter ST, Lyrer PA, Thijs V, Bersano A, Abboud S, Leys D, Grond-Ginsbach C, Kloss M, Touze E, Pezzini A, Metso AJ; CADISP Group. Migraine in cervical artery dissection and ischemic stroke patients. *Neurology*. 2012;78:1221–1228.
- Pezzini A, Granella F, Grassi M, Bertolino C, Del Zotto E, Immovilli P, Bazzoli E, Padovani A, Zanferrari C. History of migraine and the risk of spontaneous cervical artery dissection. *Cephalalgia*. 2005;25:575–580.
- Tzourio C, Benslamia L, Guillon B, Aidi S, Bertrand M, Berthet K, Bousser MG. Migraine and the risk of cervical artery dissection: a case-control study. *Neurology*. 2002;59:435–437.
- Mokri B. Dissections of cervical and cephalic arteries. In: Sundt TM Jr, ed. *Occlusive Cerebrovascular Disease: Diagnostic and Surgical Management*. Philadelphia, PA: WB Saunders; 1987:38–59.
- Mokri B, Sundt TM Jr, Houser OW, Piepgras DG. Spontaneous dissection of the cervical internal carotid artery. *Ann Neurol*. 1986;19:126–138.
- Galtes I, Borondo JC, Cos M, Subirana M, Martin-Fumado C, Castella J, Medallo J. Traumatic bilateral vertebral artery dissection. *Forensic Sci Int*. 2012;214:e12–e15.
- Naggara O, Louillet F, Touze E, Roy D, Leclerc X, Mas JL, Pruvo JP, Meder JF, Oppenheim C. Added value of high-resolution MR imaging in the diagnosis of vertebral artery dissection. *AJNR Am J Neuroradiol*. 2010;31:1707–1712.
- Naggara O, Morel A, Touze E, Raymond J, Mas JL, Meder JF, Oppenheim C. Stroke occurrence and patterns are not influenced by the degree of stenosis in cervical artery dissection. *Stroke*. 2012;43:1150–1152.
- Dittrich R, Dziewas R, Ritter MA, Kloska SP, Bachmann R, Nassenstein I, Kühlenbaumer G, Heindel W, Ringelstein EB, Nabavi DG. Negative

- ultrasound findings in patients with cervical artery dissection. Negative ultrasound in CAD. *J Neurol*. 2006;253:424–433.
32. Sturzenegger M. Spontaneous internal carotid artery dissection: early diagnosis and management in 44 patients. *J Neurol*. 1995;242:231–238.
  33. Brandt T, Hausser I, Orberk E, Grau A, Hartschuh W, Anton-Lamprecht I, Hacke W. Ultrastructural connective tissue abnormalities in patients with spontaneous cervicocerebral artery dissections. *Ann Neurol*. 1998;44:281–285.
  34. Ulbricht D, Diederich NJ, Hermanns-Le T, Metz RJ, Macian F, Pierard GE. Cervical artery dissection: an atypical presentation with Ehlers-Danlos-like collagen pathology? *Neurology*. 2004;63:1708–1710.
  35. Grond-Ginsbach C, Debette S. The association of connective tissue disorders with cervical artery dissections. *Curr Mol Med*. 2009;9:210–214.
  36. Muscat P, Lidov M, Nahar T, Tuhim S, Weinberger J. Vertebral artery dissection in Turner's syndrome: diagnosis by magnetic resonance imaging. *J Neuroimaging*. 2001;11:50–54.
  37. Vanacker P, Thijs V. Spontaneous cervical artery dissection in adult Williams syndrome. *Cerebrovasc Dis*. 2009;27:309–310.
  38. Schievink WI, Mokri B, Piepgras DG, Kuiper JD. Recurrent spontaneous arterial dissections: risk in familial versus nonfamilial disease. *Stroke*. 1996;27:622–624.
  39. Gallerini S, Morelli N, Chiti A, Baldacci F, Sonboli C, Orlandi G, Murri L. Spontaneous bilateral carotid artery dissection and hereditary haemochromatosis: what relationship? *Neurol Sci*. 2006;27:291–292.
  40. Dittich R, Heidbreder A, Rohsbach D, Schmalhorst J, Nassenstein I, Maintz D, Ringelstein EB, Nabavi DG, Kuhlbaumer G. Connective tissue and vascular phenotype in patients with cervical artery dissection. *Neurology*. 2007;68:2120–2124.
  41. Konrad C, Nabavi DG, Junker R, Dziewas R, Henningsen H, Stogbauer F. Spontaneous internal carotid artery dissection and alpha-1-antitrypsin deficiency. *Acta Neurol Scand*. 2003;107:233–236.
  42. Pezzini A, Magoni M, Corda L, Pini L, Medicina D, Crispino M, Pavia M, Padovani A, Grassi V. Alpha-1-antitrypsin deficiency-associated cervical artery dissection: report of three cases. *Eur Neurol*. 2002;47:201–204.
  43. Kloss M, Metso A, Pezzini A, Leys D, Giroud M, Metso TM, Tatlisumak T, Lichy C, Bersano A, Abboud S, Grau A, Lyrer PA, Debette S, Dallongeville J, Martin J, Caso V, Grond-Ginsbach C, Engelter ST. Towards understanding seasonal variability in cervical artery dissection (CeAD). *J Neurol*. 2012;259:1662–1667.
  44. Pezzini A, Del Zotto E, Archetti S, Negrini R, Bani P, Albertini A, Grassi M, Assanelli D, Gasparotti R, Vignolo LA, Magoni M, Padovani A. Plasma homocysteine concentration, C677T MTHFR genotype, and 844ins68bp CBS genotype in young adults with spontaneous cervical artery dissection and atherothrombotic stroke. *Stroke*. 2002;33:664–669.
  45. Pezzini A, Grassi M, Del Zotto E, Giossi A, Monastero R, Dalla Volta G, Archetti S, Zavarise P, Camarda C, Gasparotti R, Magoni M, Camarda R, Padovani A. Migraine mediates the influence of C677T MTHFR genotypes on ischemic stroke risk with a stroke-subtype effect. *Stroke*. 2007;38:3145–3151.
  46. Arauz A, Hoyos L, Cantu C, Jara A, Martinez L, Garcia I, Fernandez Mde L, Alonso E. Mild hyperhomocysteinemia and low folate concentrations as risk factors for cervical arterial dissection. *Cerebrovasc Dis*. 2007;24:210–214.
  47. Mokri B, Okazaki H. Cystic medial necrosis and internal carotid artery dissection in a Marfan sibling: partial expression of Marfan syndrome. *J Stroke Cerebrovasc Dis*. 1992;2:100–105.
  48. Raser JM, Mullen MT, Kasner SE, Cucchiara BL, Messe SR. Cervical carotid artery dissection is associated with styloid process length. *Neurology*. 2011;77:2061–2066.
  49. Longoni M, Grond-Ginsbach C, Grau AJ, Genius J, Debette S, Schwaninger M, Ferrarese C, Lichy C. The ICAM-1 E469K gene polymorphism is a risk factor for spontaneous cervical artery dissection. *Neurology*. 2006;66:1273–1275.
  50. Bobrie G, Brunet-Bourgin F, Alamowitch S, Coville P, Kassiotis P, Kermarrec A, Chauveau D. Spontaneous artery dissection: is it part of the spectrum of autosomal dominant polycystic kidney disease? *Nephrol Dial Transplant*. 1998;13:2138–2141.
  51. Genius J, Dong-Si T, Grau AP, Lichy C. Postacute C-reactive protein levels are elevated in cervical artery dissection. *Stroke*. 2005;36:e42–e44.
  52. Grau AJ, Brandt T, Bugge F, Orberk E, Mytilineos J, Werle E, Conradt, Krause M, Winter R, Hacke W. Association of cervical artery dissection with recent infection. *Arch Neurol*. 1999;56:851–856.
  53. Grau AJ, Bugge F, Ziegler C, Schwarz W, Meuser J, Tasman AJ, Buhler A, Benesch C, Becher H, Hacke W. Association between acute cerebrovascular ischemia and chronic and recurrent infection. *Stroke*. 1997;28:1724–1729.
  54. Guillon B, Berthet K, Benslamia L, Bertrand M, Bousser MG, Tzourio C. Infection and the risk of spontaneous cervical artery dissection: a case-control study. *Stroke*. 2003;34:e79–e81.
  55. Yuasa H, Tokito S, Izumi K, Hirabayashi K. Cerebrovascular moyamoya disease associated with an intracranial pseudoaneurysm: case report. *J Neurosurg*. 1982;56:131–134.
  56. Schievink WI, Michels VV, Mokri B, Piepgras DG, Perry HO. Brief report: a familial syndrome of arterial dissections with lentiginosis. *N Engl J Med*. 1995;332:576–579.
  57. Barbour PJ, Castaldo JE, Rae-Grant AD, Gee W, Reed JF 3rd, Jenny D, Longennecker J. Internal carotid artery redundancy is significantly associated with dissection. *Stroke*. 1994;25:1201–1206.
  58. Brandt T, Grond-Ginsbach C. Spontaneous cervical artery dissection: from risk factors toward pathogenesis. *Stroke*. 2002;33:657–658.
  59. Paciaroni M, Georgiadis D, Arnold M, Gandjour J, Keseru B, Fahrni G, Caso V, Baumgartner RW. Seasonal variability in spontaneous cervical artery dissection. *J Neurol Neurosurg Psychiatry*. 2006;77:677–679.
  60. Schievink WI, Wijdicks EF, Kuiper JD. Seasonal pattern of spontaneous cervical artery dissection. *J Neurosurg*. 1998;89:101–103.
  61. Debette S, Metso T, Pezzini A, Abboud S, Metso A, Leys D, Bersano A, Louillet F, Caso V, Lamy C, Medeiros E, Samson Y, Grond-Ginsbach C, Engelter ST, Thijs V, Beretta S, Bejot Y, Sessa M, Lorenza Muiesan M, Amouyel P, Castellano M, Arveiler D, Tatlisumak T, Dallongeville J; Cervical Artery Dissection and Ischemic Stroke Patients (CADISP) Group. Association of vascular risk factors with cervical artery dissection and ischemic stroke in young adults. *Circulation*. 2011;123:1537–1544.
  62. Fusco MR, Harrigan MR. Cerebrovascular dissections: a review part I: spontaneous dissections. *Neurosurgery*. 2011;68:242–257.
  63. Maroon JC, Gardner P, Abula AA, El-Kadi H, Bost J. “Golfer's stroke”: golf-induced stroke from vertebral artery dissection. *Surg Neurol*. 2007;67:163–168.
  64. Leys D, Moulin T, Stoijkovic T, Begey S, Chavot D; DONALD Investigators. Follow up of patients with history of cervical artery dissection. *Cerebrovasc Dis*. 1995;5:43–49.
  65. Touze E, Randoux B, Meary E, Arquizan C, Meder JF, Mas JL. Aneurysmal forms of cervical artery dissection: associated factors and outcome. *Stroke*. 2001;32:418–423.
  66. Albuquerque FC, Hu YC, Dashti SR, Abula AA, Clark JC, Alkire B, Theodore N, McDougall CG. Craniocervical arterial dissections as sequelae of chiropractic manipulation: patterns of injury and management. *J Neurosurg*. 2011;115:1197–1205.
  67. Cassidy JD, Boyle E, Cote P, He Y, Hogg-Johnson S, Silver FL, Bondy SJ. Risk of vertebrobasilar stroke and chiropractic care: results of a population-based case-control and case-crossover study. *Spine (Phila Pa 1976)*. 2008;33:S176–S183.
  68. Ernst E. Adverse effects of spinal manipulation: a systematic review. *J R Soc Med*. 2007;100:330–338.
  69. Harvey E, Burton AK, Moffett JK, Breen A; UK BEAM Trial Team. Spinal manipulation for low-back pain: a treatment package agreed to by the UK chiropractic, osteopathy and physiotherapy professional associations. *Man Ther*. 2003;8:46–51.
  70. Shekelle PG, Adams AH, Chassin MR, Hurwitz EL, Brook RH. Spinal manipulation for low-back pain. *Ann Intern Med*. 1992;117:590–598.
  71. Cote P, Cassidy JD, Carroll L. The treatment of neck and low back pain: who seeks care? Who goes where? *Med Care*. 2001;39:956–967.
  72. Pettman E. A history of manipulative therapy. *J Man Manip Ther*. 2007;15:165–174.
  73. Dunning JR, Cleland JA, Waldrop MA, Arnot CF, Young IA, Turner M, Sigurdsson G. Upper cervical and upper thoracic thrust manipulation versus nonthrust mobilization in patients with mechanical neck pain: a multicenter randomized clinical trial. *J Orthop Sports Phys Ther*. 2012;42:5–18.
  74. Greenman PE. *Principles of Manual Medicine*. 3rd ed. Philadelphia, PA: Lippincott Williams & Wilkins; 2003.
  75. Isaacs ER, Bookhout MR. *Bourdillon's Spinal Manipulation*. 6th ed. Boston, MA: Butterworth Heinemann; 2002.
  76. Peterson DH, Bergmann TF, eds. *Chiropractic Technique: Principles and Procedures*. 2nd ed. New York, NY: Mosby; 2002.
  77. Barnes PM, Bloom B, Nahin R. *CDC National Health Statistics Report Number 12: Complementary and Alternative Medicine Use Among Adults and Children: United States, 2007*. Atlanta, GA: Centers for Disease Control and Prevention; December 10, 2008.

78. Hurwitz EL, Coulter ID, Adams AH, Genovese BJ, Shekelle PG. Use of chiropractic services from 1985 through 1991 in the United States and Canada. *Am J Public Health*. 1998;88:771–776.
79. Coulter ID, Hurwitz EL, Adams AH, Genovese BJ, Hays R, Shekelle PG. Patients using chiropractors in North America: who are they, and why are they in chiropractic care? *Spine (Phila Pa 1976)*. 2002;27:291–296.
80. Gross A, Miller J, D'Sylva J, Burnie SJ, Goldsmith CH, Graham N, Haines T, Bronfort G, Hoving JL; COG. Manipulation or mobilisation for neck pain: a Cochrane Review. *Man Ther*. 2010;15:315–333.
81. Gatterman MI, Hansen DT. Development of chiropractic nomenclature through consensus. *J Manipulative Physiol Ther*. 1994;17:302–309.
82. Mann T, Refshauge KM. Causes of complications from cervical spine manipulation. *Aust J Physiother*. 2001;47:255–266.
83. Haldeman S, Carey P, Townsend M, Papadopoulos C. Arterial dissections following cervical manipulation: the chiropractic experience. *CMAJ*. 2001;165:905–906.
- 83a. Bronfort G, Evans R, Anderson AV, Svendsen KH, Bracha Y, Grimm RH. Spinal manipulation, medication, or home exercise with advice for acute and subacute neck pain: a randomized trial. *Ann Intern Med*. 2012;156(1 Pt 1):1–10.
84. Rothwell DM, Bondy SJ, Williams JJ. Chiropractic manipulation and stroke: a population-based case-control study. *Stroke*. 2001;32:1054–1060.
85. Thomas LC, Rivett DA, Attia JR, Parsons M, Levi C. Risk factors and clinical features of craniocervical arterial dissection. *Man Ther*. 2011;16:351–356.
86. Beatty RA. Dissecting hematoma of the internal carotid artery following chiropractic cervical manipulation. *J Trauma*. 1977;17:248–249.
87. Stringer WL, Kelly DL Jr. Traumatic dissection of the extracranial internal carotid artery. *Neurosurgery*. 1980;6:123–130.
88. Sherman DG, Hart RG, Easton JD. Abrupt change in head position and cerebral infarction. *Stroke*. 1981;12:2–6.
89. Mas JL, Henin D, Bousser MG, Chain F, Hauw JJ. Dissecting aneurysm of the vertebral artery and cervical manipulation: a case report with autopsy. *Neurology*. 1989;39:512–515.
90. Biousse V, D'Anglejan-Chatillon J, Massiou H, Bousser MG. Head pain in non-traumatic carotid artery dissection: a series of 65 patients. *Cephalalgia*. 1994;14:33–36.
91. Peters M, Bohl J, Thomke F, Kallen KJ, Mahlzahn K, Wandel E, Meyer zum Buschenfelde KH. Dissection of the internal carotid artery after chiropractic manipulation of the neck. *Neurology*. 1995;45:2284–2286.
92. Hufnagel A, Hammers A, Schonle PW, Bohm KD, Leonhardt G. Stroke following chiropractic manipulation of the cervical spine. *J Neurol*. 1999;246:683–688.
93. Ghosh IR, Langford RM, Nieminen K, Kari A, Takala J. Repetitive synchronized cyclical oscillations of multisystem parameters subsequent to high-dose thiopental therapy for status epilepticus secondary to herpes encephalitis. *Br J Anaesth*. 2000;85:471–473.
94. Reker DM, Hamilton BB, Duncan PW, Yeh SC, Rosen A. Stroke: who's counting what? *J Rehabil Res Dev*. 2001;38:281–289.
95. Haldeman S, Carey P, Townsend M, Papadopoulos C. Clinical perceptions of the risk of vertebral artery dissection after cervical manipulation: the effect of referral bias. *Spine J*. 2002;2:334–342.
96. Haldeman S, Kohlbeck FJ, McGregor M. Unpredictability of cerebrovascular ischemia associated with cervical spine manipulation therapy: a review of sixty-four cases after cervical spine manipulation. *Spine (Phila Pa 1976)*. 2002;27:49–55.
97. Beaudry M, Spence JD. Motor vehicle accidents: the most common cause of traumatic vertebral artery dissection. *Can J Neurol Sci*. 2003;30:320–325.
98. Dziewas R, Konrad C, Drager B, Evers S, Besselmann M, Ludemann P, Kühlenbaumer G, Stogbauer F, Ringelstein EB. Cervical artery dissection: clinical features, risk factors, therapy and outcome in 126 patients. *J Neurol*. 2003;250:1179–1184.
99. Christian MD, Detsky AS. Clinical problem-solving: a twist of fate? *N Engl J Med*. 2004;351:69–73.
100. Bartels E. Dissection of the extracranial vertebral artery: clinical findings and early noninvasive diagnosis in 24 patients. *J Neuroimaging*. 2006;16:24–33.
101. Reuter U, Hamling M, Kavuk I, Einhaupl KM, Schielke E. Vertebral artery dissections after chiropractic neck manipulation in Germany over three years. *J Neurol*. 2006;253:724–730.
102. Kawchuk GN, Jhangri GS, Hurwitz EL, Wynd S, Haldeman S, Hill MD. The relation between the spatial distribution of vertebral artery compromise and exposure to cervical manipulation. *J Neurol*. 2008;255:371–377.
103. Miley ML, Wellik KE, Wingerchuk DM, Demaerschalk BM. Does cervical manipulative therapy cause vertebral artery dissection and stroke? *Neurologist*. 2008;14:66–73.
104. Choi S, Boyle E, Cote P, Cassidy JD. A population-based case-series of Ontario patients who develop a vertebral artery stroke after seeing a chiropractor. *J Manipulative Physiol Ther*. 2011;34:15–22.
105. Lee MJ, Park YG, Kim SJ, Lee JJ, Bang OY, Kim JS. Characteristics of stroke mechanisms in patients with medullary infarction. *Eur J Neurol*. 2012;19:1433–1439.
106. Thiel HW, Bolton JE, Docherty S, Portlock JC. Safety of chiropractic manipulation of the cervical spine: a prospective national survey. *Spine (Phila Pa 1976)*. 2007;32:2375–2378.
107. Humphreys BK, Peterson CK, Muehleman D, Haueter P. Are Swiss chiropractors different than other chiropractors? Results of the job analysis survey 2009. *J Manipulative Physiol Ther*. 2010;33:519–535.
108. Norris JW, Beletsky V, Nadareishvili ZG. Sudden neck movement and cervical artery dissection: the Canadian Stroke Consortium. *CMAJ*. 2000;163:38–40.
109. Ernst E. Life-threatening complications of spinal manipulation. *Stroke*. 2001;32:809–810.
110. Kapral MK, Bondy SJ. Cervical manipulation and risk of stroke. *CMAJ*. 2001;165:907–908.
111. Ernst E. Spinal manipulation: its safety is uncertain. *CMAJ*. 2002;166:40–41.
112. Williams LS, Biller J. Vertebrobasilar dissection and cervical spine manipulation: a complex pain in the neck. *Neurology*. 2003;60:1408–1408.
113. Redwood D. Chiropractic and visceral disorders. *J Altern Complement Med*. 2007;13:479–480.
114. Ellekjaer H, Holmen J, Kruger O, Terent A. Identification of incident stroke in Norway: hospital discharge data compared with a population-based stroke register. *Stroke*. 1999;30:56–60.
115. Boyle E, Cote P, Grier AR, Cassidy JD. Examining vertebral artery stroke in two Canadian provinces. *Spine (Phila Pa 1976)*. 2008;33:S170–S175.
116. Wang JJ, Attia J. Study designs in epidemiology and levels of evidence. *Am J Ophthalmol*. 2010;149:367–370.
117. Smith WS, Johnston SC, Skalarin EJ, Weaver M, Azari P, Albers GW, Gress DR. Spinal manipulative therapy is an independent risk factor for vertebral artery dissection. *Neurology*. 2003;60:1424–1428.
118. Engelter ST, Grond-Ginsbach C, Metso TM, Metso AJ, Kloss M, Debette S, Leys D, Grau A, Dallongeville J, Bodenat M, Samson Y, Caso V, Pezzini A, Bonati LH, Thijs V, Gensicke H, Martin JJ, Bersano A, Touze E, Tatlisumak T, Lyrer PA, Brandt T; Cervical Artery Dissection and Ischemic Stroke Patients Study Group. Cervical artery dissection: trauma and other potential mechanical trigger events. *Neurology*. 2013;80:1950–1957.
119. Thomas LC, Rivett DA, Attia JR, Levi CR. Risk factors and clinical presentation of craniocervical arterial dissection: a prospective study. *BMC Musculoskelet Disord*. 2012;13:164.
120. Horwitz RI, Feinstein AR. The problem of “protopathic bias” in case-control studies. *Am J Med*. 1980;68:255–258.
121. Naderi S, Andalkar N, Benzel E. History of spine biomechanics, part I: the pre-Greco-Roman, Greco-Roman, and medieval roots of spine biomechanics. *Neurosurgery*. 2007;60:382–390.
122. Naderi S, Andalkar N, Benzel EC. History of spine biomechanics, part II: from the Renaissance to the 20th century. *Neurosurgery*. 2007;60:392–403.
123. Herzog W. The biomechanics of spinal manipulation. *J Bodyw Mov Ther*. 2010;14:280–286.
124. Austin N, DiFrancesco LM, Herzog W. Microstructural damage in arterial tissue exposed to repeated tensile strains. *J Manipulative Physiol Ther*. 2010;33:14–19.
125. Bowler N, Shamley D, Davies R. The effect of a simulated manipulation position on internal carotid and vertebral artery blood flow in healthy individuals. *Man Ther*. 2011;16:87–93.
126. Haynes M, Milne N. Color duplex sonographic findings in human vertebral arteries during cervical rotation. *J Clin Ultrasound*. 2001;29:14–24.
127. Herzog W, Leonard TR, Symons B, Tang C, Wuest S. Vertebral artery strains during high-speed, low amplitude cervical spinal manipulation. *J Electromyogr Kinesiol*. 2012;22:740–746.
128. Kawchuk GN, Wynd S, Anderson T. Defining the effect of cervical manipulation on vertebral artery integrity: establishment of an animal model. *J Manipulative Physiol Ther*. 2004;27:539–546.
129. Haldeman S, Kohlbeck FJ, McGregor M. Risk factors and precipitating neck movements causing vertebral artery dissection after



- cervical trauma and spinal manipulation. *Spine (Phila PA 1976)*. 1999;24:785–794.
130. Haneline M, Triano J. Cervical artery dissection: a comparison of highly dynamic mechanisms: manipulation versus motor vehicle collision. *J Manipulative Physiol Ther*. 2005;28:57–63.
  131. Creighton D, Kondrtek M, Krauss J, Huijbregts P, Qu H. Ultrasound analysis of the vertebral artery during non-thrust cervical translatory spinal manipulation. *J Man Manip Ther*. 2011;19:84–90.
  132. Bogduk N, Mercer S. Biomechanics of the cervical spine, I: normal kinematics. *Clin Biomech (Bristol, Avon)*. 2000;15:633–648.
  133. Swartz EE, Floyd RT, Cendoma M. Cervical spine functional anatomy and the biomechanics of injury due to compressive loading. *J Athl Train*. 2005;40:155–161.
  134. Ishii T, Mukai Y, Hosono N, Sakaura H, Fujii R, Nakajima Y, Tamura S, Sugamoto K, Yoshikawa H. Kinematics of the subaxial cervical spine in rotation in vivo three-dimensional analysis. *Spine (Phila Pa 1976)*. 2004;29:2826–2831.
  135. Thiel HW. Gross morphology and pathoanatomy of the vertebral arteries. *J Manipulative Physiol Ther*. 1991;14:133–141.
  136. Herzog W, Conway PJ, Kawchuk GN, Zhang Y, Hasler EM. Forces exerted during spinal manipulative therapy. *Spine (Phila Pa 1976)*. 1993;18:1206–1212.
  137. Symons BP, Leonard T, Herzog W. Internal forces sustained by the vertebral artery during spinal manipulative therapy. *J Manipulative Physiol Ther*. 2002;25:504–510.
  138. Gal J, Herzog W, Kawchuk G, Conway PJ, Zhang YT. Movements of vertebrae during manipulative thrusts to unembalmed human cadavers. *J Manipulative Physiol Ther*. 1997;20:30–40.
  139. Downie A, Vemulpad S, Bull PW. Quantifying the high-velocity, low-amplitude spinal manipulative thrust: a systematic review. *J Manipulative Physiol Ther*. 2010;33:542–553.
  140. Van Zoest GG, Gosselin G. Three-dimensionality of direct contact forces in chiropractic spinal manipulative therapy. *J Manipulative Physiol Ther*. 2003;26:549–556.
  141. Wuest S, Symons B, Leonard T, Herzog W. Preliminary report: biomechanics of vertebral artery segments C1–C6 during cervical spinal manipulation. *J Manipulative Physiol Ther*. 2010;33:273–278.
  142. Symons B, Wuest S, Leonard T, Herzog W. Biomechanical characterization of cervical spinal manipulation in living subjects and cadavers. *J Electromyogr Kinesiol*. 2012;22:747–751.
  143. Snodgrass SJ, Rivett DA, Robertson VJ. Manual forces applied during cervical mobilization. *J Manipulative Physiol Ther*. 2007;30:17–25.
  144. Ozdemir H. Effects of cervical rotation on hemodynamics in vertebral arteries. *J Diagn Med Sonogr*. 2005;21:384–391.
  145. Sakaguchi M, Kitagawa K, Hougaku H, Hashimoto H, Nagai Y, Yamagami H, Ohtsuki T, Oku N, Hashikawa K, Matsushita K, Matsumoto M, Hori M. Mechanical compression of the extracranial vertebral artery during neck rotation. *Neurology*. 2003;61:845–847.
  146. Barton JW, Margolis MT. Rotational obstructions of the vertebral artery at the atlantoaxial joint. *Neuroradiology*. 1975;9:117–120.
  147. Weintraub MI, Khoury A. Critical neck position as an independent risk factor for posterior circulation stroke: a magnetic resonance angiographic analysis. *J Neuroimaging*. 1995;5:16–22.
  148. Wynd S, Anderson T, Kawchuk G. Effect of cervical spine manipulation on a pre-existing vascular lesion within the canine vertebral artery. *Cerebrovasc Dis*. 2008;26:304–309.
  149. Braun IF, Pinto RS, De Filipp GJ, Lieberman A, Pasternack P, Zimmerman RD. Brain stem infarction due to chiropractic manipulation of the cervical spine. *South Med J*. 1983;76:1507–1510.
  150. Paciaroni M, Bogousslavsky J. Cerebrovascular complications of neck manipulation. *Eur Neurol*. 2009;61:112–118.
  151. Brownson RJ, Zollinger WK, Madeira T, Fell D. Sudden sensorineural hearing loss following manipulation of the cervical spine. *Laryngoscope*. 1986;96:166–170.
  152. Assendelft WJ, Bouter LM, Knipschild PG. Complications of spinal manipulation: a comprehensive review of the literature. *J Fam Pract*. 1996;42:475–480.
  153. Leon-Sanchez A, Cuether A, Ferrer G. Cervical spine manipulation: an alternative medical procedure with potentially fatal complications. *South Med J*. 2007;100:201–203.
  154. Schellhas KP, Latchaw RE, Wendling LR, Gold LH. Vertebrobasilar injuries following cervical manipulation. *JAMA*. 1980;244:1450–1453.
  155. Morton A. Internal carotid artery dissection following chiropractic treatment in a pregnant woman with systemic lupus erythematosus. *Chiropr Man Therap*. 2012;20:38.
  156. Haneline MT, Croft AC, Frishberg BM. Association of internal carotid artery dissection and chiropractic manipulation. *Neurologist*. 2003;9:35–44.
  157. Dandamudi VS, Thaler DE, Malek AM. Cerebral embolus following chiropractic manipulation in a patient with a calcified carotid artery. *J Neuroimaging*. 2013;9:429–430.
  158. Herzog W, Tang C, Leonard T. Internal carotid artery strains during high-speed, low-amplitude spinal manipulations of the neck [published online ahead of print November 6, 2012]. *J Manipulative Physiol Ther*. doi: 10.1016/j.jmpt.2012.09.005. <http://www.ncbi.nlm.nih.gov/pubmed/23140796>. Accessed April 30, 2013.
  159. Arnold M, Bousser MG. Clinical manifestations of vertebral artery dissection. *Front Neurol Neurosci*. 2005;20:77–86.
  160. Metso TM, Metso AJ, Salonen O, Haapaniemi E, Putaala J, Arto V, Helenius J, Kaste M, Tatlisumak T. Adult cervicocerebral artery dissection: a single-center study of 301 Finnish patients. *Eur J Neurol*. 2009;16:656–661.
  161. Haneline MT, Lewkovich GN. An analysis of the etiology of cervical artery dissections: 1994 to 2003. *J Manipulative Physiol Ther*. 2005;28:617–622.
  162. Nadgir RN, Loevner LA, Ahmed T, Moonis G, Chalela J, Slawek K, Imbesi S. Simultaneous bilateral internal carotid and vertebral artery dissection following chiropractic manipulation: case report and review of the literature. *Neuroradiology*. 2003;45:311–314.
  163. Arnold M, Bousser MG, Fahmi G, Fischer U, Georgiadis D, Gandjour J, Benninger D, Sturzenegger M, Mattle HP, Baumgartner RW. Vertebral artery dissection: presenting findings and predictors of outcome. *Stroke*. 2006;37:2499–2503.
  164. Bioussé V, D'Anglejan-Chatillon J, Touboul PJ, Amarenco P, Bousser MG. Time course of symptoms in extracranial carotid artery dissections: a series of 80 patients. *Stroke*. 1995;26:235–239.
  165. Debette S, Leys D. Cervical-artery dissections: predisposing factors, diagnosis, and outcome. *Lancet Neurol*. 2009;8:668–678.
  166. Hardmeier M, Haller S, Steck A, Lyrer P, Engelter S, Renaud S. Vertebral artery dissection presenting with fifth cervical root (C5) radiculopathy. *J Neurol*. 2007;254:672–673.
  167. Hart RG, Easton JD. Dissections of cervical and cerebral arteries. *Neurol Clin*. 1983;1:155–182.
  168. Mokri B, Silbert PL, Schievink WI, Piepgras DG. Cranial nerve palsy in spontaneous dissection of the extracranial internal carotid artery. *Neurology*. 1996;46:356–359.
  169. Silbert PL, Mokri B, Schievink WI. Headache and neck pain in spontaneous internal carotid and vertebral artery dissections. *Neurology*. 1995;45:1517–1522.
  170. Sturzenegger M. Headache and neck pain: the warning symptoms of vertebral artery dissection. *Headache*. 1994;34:187–193.
  171. Gottesman RF, Sharma P, Robinson KA, Arnan M, Tsui M, Ladha K, Newman-Toker DE. Clinical characteristics of symptomatic vertebral artery dissection: a systematic review. *Neurologist*. 2012;18:245–254.
  172. Dunne JW, Conacher GN, Khangure M, Harper CG. Dissecting aneurysms of the vertebral arteries following cervical manipulation: a case report. *J Neurol Neurosurg Psychiatry*. 1987;50:349–353.
  173. Baumgartner RW, Arnold M, Baumgartner I, Mosso M, Gonner F, Studer A, Schroth G, Schuknecht B, Sturzenegger M. Carotid dissection with and without ischemic events: local symptoms and cerebral artery findings. *Neurology*. 2001;57:827–832.
  174. Petro GR, Witwer GA, Cacayorin ED, Hodge CJ, Bredenberg CE, Jastremski MS, Kieffer SA. Spontaneous dissection of the cervical internal carotid artery: correlation of arteriography, CT, and pathology. *AJR Am J Roentgenol*. 1987;148:393–398.
  175. Kitanaka C, Tanaka J, Kuwahara M, Teraoka A. Magnetic resonance imaging study of intracranial vertebrobasilar artery dissections. *Stroke*. 1994;25:571–575.
  176. Goldberg HI, Grossman RI, Gomori JM, Asbury AK, Bilaniuk LT, Zimmerman RA. Cervical internal carotid artery dissecting hemorrhage: diagnosis using MR. *Radiology*. 1986;158:157–161.
  177. Huston J 3rd, Bernstein MA, Riederer SJ. Feathering: vertebral artery pseudostenosis with elliptical centric contrast-enhanced MR angiography. *AJNR Am J Neuroradiol*. 2006;27:850–852.
  178. Schievink WI. The treatment of spontaneous carotid and vertebral artery dissections. *Curr Opin Cardiol*. 2000;15:316–321.
  179. Berger MS, Wilson CB. Intracranial dissecting aneurysms of the posterior circulation: report of six cases and review of the literature. *J Neurosurg*. 1984;61:882–894.
  180. Caplan LR, Baquis GD, Pessin MS, D'Alton J, Adelman LS, DeWitt LD, Ho K, Izukawa D, Kwan ES. Dissection of the intracranial vertebral artery. *Neurology*. 1988;38:868–877.

181. Friedman AH, Drake CG. Subarachnoid hemorrhage from intracranial dissecting aneurysm. *J Neurosurg.* 1984;60:325–334.
182. Halbach VV, Higashida RT, Dowd CF, Fraser KW, Smith TP, Teitelbaum GP, Wilson CB, Hieshima GB. Endovascular treatment of vertebral artery dissections and pseudoaneurysms. *J Neurosurg.* 1993;79:183–191.
183. Kitahara C, Sasaki T, Eguchi T, Teraoka A, Nakane M, Hoya K. Intracranial vertebral artery dissections: clinical, radiological features, and surgical considerations. *Neurosurgery.* 1994;34:620–626.
184. Sasaki O, Ogawa H, Koike T, Koizumi T, Tanaka R. A clinicopathological study of dissecting aneurysms of the intracranial vertebral artery. *J Neurosurg.* 1991;75:874–882.
185. Lansberg MG, Albers GW, Beaulieu C, Marks MP. Comparison of diffusion-weighted MRI and CT in acute stroke. *Neurology.* 2000;54:1557–1561.
186. Nebelsieck J, Sengelhoff C, Nassenstein I, Maintz D, Kühlenbaumer G, Nabavi DG, Ringelstein EB, Dittich R. Sensitivity of neurovascular ultrasound for the detection of spontaneous cervical artery dissection. *J Clin Neurosci.* 2009;16:79–82.
187. Arnold M, Baumgartner RW, Stapf C, Nedeltchev K, Buffon F, Benninger D, Georgiadis D, Sturzenegger M, Mattle HP, Boussier MG. Ultrasound diagnosis of spontaneous carotid dissection with isolated Horner syndrome. *Stroke.* 2008;39:82–86.
188. Vertinsky AT, Schwartz NE, Fischbein NJ, Rosenberg J, Albers GW, Zaharchuk G. Comparison of multidetector CT angiography and MR imaging of cervical artery dissection. *AJNR Am J Neuroradiol.* 2008;29:1753–1760.
189. Lum C, Chakraborty S, Schlossmacher M, Santos M, Mohan R, Sinclair J, Sharma M. Vertebral artery dissection with a normal-appearing lumen at multisession CT angiography: the importance of identifying wall hematoma. *AJNR Am J Neuroradiol.* 2009;30:787–792.
190. Chen CJ, Tseng YC, Lee TH, Hsu HL, See LC. Multisession CT angiography compared with catheter angiography in diagnosing vertebral artery dissection. *AJNR Am J Neuroradiol.* 2004;25:769–774.
191. Provenzale JM. Dissection of the internal carotid and vertebral arteries: imaging features. *AJR Am J Roentgenol.* 1995;165:1099–1104.
192. Rodallec MH, Marteau V, Gerber S, Desmottes L, Zins M. Craniocervical arterial dissection: spectrum of imaging findings and differential diagnosis. *Radiographics.* 2008;28:1711–1728.
193. Masdeu JC, Irimia P, Asenbaum S, Bogousslavsky J, Brainin M, Chabriet H, Herholz K, Markus HS, Martinez-Vila E, Niederkorn K, Schellinger PD, Seitz RJ; EFNS. EFNS guideline on neuroimaging in acute stroke: report of an EFNS task force. *Eur J Neurol.* 2006;13:1271–1283.
194. Lyrer P, Engelter S. Antithrombotic drugs for carotid artery dissection. *Cochrane Database Syst Rev.* 2010;(10):CD000255.
195. Pelkonen O, Tikkakoski T, Pyhtinen J, Sotaniemi K. Cerebral CT and MRI findings in cervicocephalic artery dissection. *Acta Radiol.* 2004;45:259–265.
196. Kurata A, Ohmomo T, Miyasaka Y, Fujii K, Kan S, Kitahara T. Coil embolization for the treatment of ruptured dissecting vertebral aneurysms. *AJNR Am J Neuroradiol.* 2001;22:11–18.
197. Conforto AB, Yamamoto F, Evaristo EF, Puglia P Jr, Caldas JG, Scaff M. Intracranial vertebral artery dissection presenting as subarachnoid hemorrhage: successful endovascular treatment. *Acta Neurol Scand.* 2001;103:64–68.
198. Willing SJ, Skidmore F, Donaldson J, Nobo UL, Chernukha K. Treatment of acute intracranial vertebrobasilar dissection with angioplasty and stent placement: report of two cases. *AJNR Am J Neuroradiol.* 2003;24:985–989.
199. Ahn JY, Han IB, Kim TG, Yoon PH, Lee YJ, Lee BH, Seo SH, Kim DI, Hong CK, Joo JY. Endovascular treatment of intracranial vertebral artery dissections with stent placement or stent-assisted coiling. *AJNR Am J Neuroradiol.* 2006;27:1514–1520.
200. Yamada M, Kitahara T, Kurata A, Fujii K, Miyasaka Y. Intracranial vertebral artery dissection with subarachnoid hemorrhage: clinical characteristics and outcomes in conservatively treated patients. *J Neurosurg.* 2004;101:25–30.
201. Metso TM, Metso AJ, Helenius J, Haapaniemi E, Salonen O, Porras M, Hernesniemi J, Kaste M, Tatlisumak T. Prognosis and safety of anticoagulation in intracranial artery dissections in adults. *Stroke.* 2007;38:1837–1842.
202. Ro A, Kageyama N, Abe N, Takatsu A, Fukunaga T. Intracranial vertebral artery dissection resulting in fatal subarachnoid hemorrhage: clinical and histopathological investigations from a medicolegal perspective. *J Neurosurg.* 2009;110:948–954.
203. Furie KL, Kasner SE, Adams RJ, Albers GW, Bush RL, Fagan SC, Halperin JL, Johnston SC, Katzan I, Kernan WN, Mitchell PH, Ovbiagele B, Palesch YY, Sacco RL, Schwamm LH, Wassertheil-Smoller S, Turan TN, Wentworth D; on behalf of the American Heart Association Stroke Council, Council on Cardiovascular Nursing, Council on Clinical Cardiology, and Interdisciplinary Council on Quality of Care and Outcomes Research. Guidelines for the prevention of stroke in patients with stroke or transient ischemic attack: a guideline for healthcare professionals from the American Heart Association/American Stroke Association. *Stroke.* 2011;42:227–276.
204. Ansari SA, Parmar H, Ibrahim M, Gemmete JJ, Gandhi D. Cervical dissections: diagnosis, management, and endovascular treatment. *Neuroimaging Clin N Am.* 2009;19:257–270.
205. Bosiers M, Callaert J, Deloof K, Verbist J, Keirse K, Peeters P. The role of carotid artery stenting for recent cerebral ischemia. *J Cardiovasc Surg (Torino).* 2010;51:293–304.
206. Cerutti D, Bonafe A, Pelouze GA, Kassem Z, Filipov R, Runavot G, Cassarini JF, Sablot D. Endovascular stent-assisted angioplasty after cervical arteries dissection [in French]. *Rev Neurol (Paris).* 2010;166:333–336.
207. Pham MH, Rahme RJ, Arnaout O, Hurley MC, Bernstein RA, Batjer HH, Bendok BR. Endovascular stenting of extracranial carotid and vertebral artery dissections: a systematic review of the literature. *Neurosurgery.* 2011;68:856–866.
208. Sheikh SI, Singhal AB. Extension of “roller coaster dissection” after tissue plasminogen activator. *AJNR Am J Neuroradiol.* 2010;31:E4.
209. Zinkstok SM, Vergouwen MD, Engelter ST, Lyrer PA, Bonati LH, Arnold M, Mattle HP, Fischer U, Sarikaya H, Baumgartner RW, Georgiadis D, Odier C, Michel P, Putaala J, Griebbe M, Wahlgren N, Ahmed N, van Geloven N, de Haan RJ, Nederkoorn PJ. Safety and functional outcome of thrombolysis in dissection-related ischemic stroke: a meta-analysis of individual patient data. *Stroke.* 2011;42:2515–2520.
210. Qureshi AI, Chaudhry SA, Hassan AE, Zacharatos H, Rodriguez GJ, Suri MF, Lakshminarayanan K, Ezzeddine MA. Thrombolytic treatment of patients with acute ischemic stroke related to underlying arterial dissection in the United States. *Arch Neurol.* 2011;68:1536–1542.
211. Kennedy F, Lanfranco S, Hicks C, Reid J, Gompertz P, Price C, Kerry S, Norris J, Markus HS; CADISS Investigators. Antiplatelets vs anticoagulation for dissection: CADISS nonrandomized arm and meta-analysis. *Neurology.* 2012;79:686–689.
212. Menon RK, Markus HS, Norris JW. Results of a UK questionnaire of diagnosis and treatment in cervical artery dissection. *J Neurol Neurosurg Psychiatry.* 2008;79:612.
213. Lyrer P, Engelter S. Antithrombotic drugs for carotid artery dissection. *Stroke.* 2004;35:613–614.
214. Lansberg MG, O'Donnell MJ, Khatri P, Lang ES, Nguyen-Huynh MN, Schwartz NE, Sonnenberg FA, Schulman S, Vandvik PO, Spencer FA, Alonso-Coello P, Guyatt GH, Akl EA; American College of Chest Physicians. Antithrombotic and thrombolytic therapy for ischemic stroke: Antithrombotic Therapy and Prevention of Thrombosis, 9th ed: American College of Chest Physicians Evidence-Based Clinical Practice Guidelines. *Chest.* 2012;141:e601S–636S.
215. Desfontaines P, Despland PA. Dissection of the internal carotid artery: aetiology, symptomatology, clinical and neurosonological follow-up, and treatment in 60 consecutive cases. *Acta Neurol Belg.* 1995;95:226–234.
216. Saeed AB, Shuaib A, Al-Sulaiti G, Emery D. Vertebral artery dissection: warning symptoms, clinical features and prognosis in 26 patients. *Can J Neurol Sci.* 2000;27:292–296.
217. Gonzales-Portillo F, Bruno A, Biller J. Outcome of extracranial cervicocephalic arterial dissections: a follow-up study. *Neurol Res.* 2002;24:395–398.
218. Beletsky V, Nadareishvili Z, Lynch J, Shuaib A, Woolfenden A, Norris JW; Canadian Stroke Consortium. Cervical arterial dissection: time for a therapeutic trial? *Stroke.* 2003;34:2856–2860.
219. de Bray JM, Marc G, Pautot V, Vielle B, Pasco A, Lhoste P, Dubas F. Fibromuscular dysplasia may herald symptomatic recurrence of cervical artery dissection. *Cerebrovasc Dis.* 2007;23:448–452.
220. Arauz A, Marquez JM, Artigas C, Balderrama J, Orrego H. Recanalization of vertebral artery dissection. *Stroke.* 2010;41:717–721.
221. Arnold M, De Marchis GM, Stapf C, Baumgartner RW, Nedeltchev K, Buffon F, Galimani A, Sarikaya H, Mattle HP, Boussier MG. Triple and quadruple spontaneous cervical artery dissection: presenting characteristics and long-term outcome. *J Neurol Neurosurg Psychiatry.* 2009;80:171–174.
222. Debette S, Grond-Ginsbach C, Bodenmann M, Kloss M, Engelter S, Metso T, Pezzini A, Brandt T, Caso V, Touze E, Metso A, Canaple S, Abboud S, Giacalone G, Lyrer P, Del Zotto E, Giroud M, Samson Y, Dallongeville

- J, Tatlisumak T, Leys D, Martin JJ; Cervical Artery Dissection Ischemic Stroke Patients (CADISP) Group. Differential features of carotid and vertebral artery dissections: the CADISP study. *Neurology*. 2011;77:1174–1181.
223. Arauz A, Hoyos L, Espinoza C, Cantu C, Barinagarrementeria F, Roman G. Dissection of cervical arteries: long-term follow-up study of 130 consecutive cases. *Cerebrovasc Dis*. 2006;22:150–154.
224. Touze E, Gauvrit JY, Meder JF, Mas JL. Prognosis of cervical artery dissection. *Front Neurol Neurosci*. 2005;20:129–139.
225. Kremer C, Mosso M, Georgiadis D, Stockli E, Benninger D, Arnold M, Baumgartner RW. Carotid dissection with permanent and transient occlusion or severe stenosis: long-term outcome. *Neurology*. 2003;60:271–275.
226. Fischer U, Ledermann I, Nedeltchev K, Meier N, Gralla J, Sturzenegger M, Mattle HP, Arnold M. Quality of life in survivors after cervical artery dissection. *J Neurol*. 2009;256:443–449.
227. Silvestrini M, Altamura C, Cerqua R, Pedone C, Balucani C, Luzzi S, Bartolini M, Provinciali L, Vernieri F. Early activation of intracranial collateral vessels influences the outcome of spontaneous internal carotid artery dissection. *Stroke*. 2011;42:139–143.
228. Hamann G, Felber S, Haas A, Stristmatter M, Kujat C, Schimrigk K, Piepgras U. Cervicocephalic artery dissections due to chiropractic manipulations. *Lancet*. 1993;341:764–765.
229. Mokri B. Traumatic and spontaneous extracranial internal carotid artery dissections. *J Neurol*. 1990;237:356–361.
230. Caso V, Paciaroni M, Corea F, Hamam M, Milia P, Pelliccioli GP, Parnetti L, Gallai V. Recanalization of cervical artery dissection: influencing factors and role in neurological outcome. *Cerebrovasc Dis*. 2004;17:93–97.
231. Guillon B, Brunereau L, Bioussé V, Djouhri H, Levy C, Bousser MG. Long-term follow-up of aneurysms developed during extracranial internal carotid artery dissection. *Neurology*. 1999;53:117–122.
232. Benninger DH, Gandjour J, Georgiadis D, Stockli E, Arnold M, Baumgartner RW. Benign long-term outcome of conservatively treated cervical aneurysms due to carotid dissection. *Neurology*. 2007;69:486–487.
233. Bassetti C, Carruzzo A, Sturzenegger M, Tuncdogan E. Recurrence of cervical artery dissection: a prospective study of 81 patients. *Stroke*. 1996;27:1804–1807.
234. Touze E, Gauvrit JY, Moulin T, Meder JF, Bracard S, Mas JL; Multicenter Survey on Natural History of Cervical Artery Dissection. Risk of stroke and recurrent dissection after a cervical artery dissection: a multicenter study. *Neurology*. 2003;61:1347–1351.
235. Georgiadis D, Arnold M, von Buedingen HC, Valko P, Sarikaya H, Rousson V, Mattle HP, Bousser MG, Baumgartner RW. Aspirin vs anticoagulation in carotid artery dissection: a study of 298 patients. *Neurology*. 2009;72:1810–1815.
236. Dittrich R, Nassenstein I, Bachmann R, Maintz D, Nabavi DG, Heindel W, Kühlenbaumer G, Ringelstein EB. Polyarterial clustered recurrence of cervical artery dissection seems to be the rule. *Neurology*. 2007;69:180–186.